

Ultrasound Imaging of the Distal Radioulnar Joint: A
new method to assess ulna radial translation in
forearm rotation

Christie Oldfield

A thesis submitted to

Auckland University of Technology in partial
fulfilment of the requirements for the degree

Of

Master of Health Science (MHSc)

2012

School of Rehabilitation and Occupational Studies

Faculty of Health and Environmental Science

Table of Contents

List of Abbreviations	4
List of Figures	6
List of Tables	8
Attestation of Authorship	9
Acknowledgements	10
Abstract	11
CHAPTER ONE - INTRODUCTION	13
CHAPTER TWO – LITERATURE REVIEW	15
2.1 Background	15
2.2 Anatomy and Kinematics of the DRUJ and surrounding structures	16
2.2 Biomechanics of the DRUJ and surrounding structures	25
2.4 Pathophysiology	27
2.4.1 Distal radius fracture	27
2.4.3 Distal radioulnar joint dislocation	29
2.4.4 Arthritis	29
2.5 Current diagnostic methods	30
2.5.1 Radiography	30
2.5.2 Magnetic resonance imaging	32
2.5.3 Computerised Tomography	33
2.5.4 Ultrasound Imaging	46
CHAPTER THREE - EXPERIMENTAL AIMS AND HYPOTHESIS	57
3.1 Research question	57
3.2 Study Aims	57
CHAPTER FOUR – EXPERIMENTAL DESIGN	58
4.1 Study Design	58
4.2 Ethics	58
4.3 Participants	59
4.4 USI Protocol	60
4.4.1 Set up	60
4.4.2 Elbow and Forearm positions	60
4.4.3 DRUJ Location and Identification	62
4.4.5 Scanning procedure	66
4.5 Image Analysis	68
CHAPTER FIVE – RESULTS	70
5.1 Demographics	70

5.2 Forearm positions and states	70
5.4 Repeatability	74
5.4.1 Within session	74
5.4.2 Inter-session	75
5.5 Validity	77
CHAPTER SIX – DISCUSSION AND CLINICAL IMPLICATIONS	78
6.1 Study design	78
6.1.1 Probe selection.	78
6.1.2 Participant positioning	79
6.1.3 Line drawing analyses	81
6.2 Bony Landmarks and anatomical variations	82
6.3 Interpretation of results	88
6.3.1 Mean translation values	88
6.3.2 Repeatability	89
6.3.3 Validity	92
6.4 Limitations of the Study	93
6.5 Clinical, Socio-economic and Research Implications	95
CHAPTER SEVEN - CONCLUSION	97
References	98
APPENDIX A	103
APPENDIX B	105
APPENDIX C	108
APPENDIX D	110

List of Abbreviations

DRUJ	Distal radioulnar joint
USI	Ultrasound imaging
RUSI	Rehabilitative ultrasound imaging
CT	Computerised tomography
MRI	Magnetic resonance imaging
TFCC	Triangular fibrocartilage complex
PRUL	Palmar radioulnar ligament
DRUL	Dorsal radioulnar ligament
UCL	Ulna collateral ligament
PQ	Pronator quadratus
ECU	Extensor carpi ulnaris
RUL	Radioulnar line
RUR	Radioulnar ratio
RASR	Radioulnar subluxation ratio
PPV	Positive predictive value
NPV	Negative predictive value
GHJ	Glenohumeral joint
ACJ	Acromioclavicular joint
MCPJ	Metacarpophalangeal joint
TMJ	Temporomandibular joint
ICC	Intraclass correlation coefficient
ECRL	Extensor carpi radialis longus
ECRB	Extensor carpi radialis brevis
EPL	Extensor pollicis longus
EI	Extensor Indicis

EDC	Extensor digitorum communis
EDM	Extensor digiti minimi
FCU	Flexor carpi ulnaris
SPSS	Statistical package for social sciences
AUT	Auckland University of Technology
AUTEC	Auckland University of Technology ethical committee
ASHT	American Society of Hand Therapists
ANOVA	Analysis of variance

List of Figures

Figure 1: TFCC and supporting ligaments.	17
Figure 2: Functional role of the DRUJ ligaments.....	18
Figure 3: RUL's through rotation	18
Figure 4: Cadaver sections of the DRUJ in relation to the radiocarpal joint and the sigmoid notch of the radius.....	25
Figure 5: Cadaver sections showing the articular seat volarly then dorsally.....	25
Figure 6: Radial deformities associated with DRUJ instability	28
Figure 7: Radial height in mm	30
Figure 8: A radiological method for assessing ulna variance	31
Figure 9: The original RUL or Mino method.....	34
Figure 10: The modified RUL method	35
Figure 11: Ratio Epicentre method	36
Figure 12: Graded Epicentre method	36
Figure 13: The congruity method	38
Figure 14: The RUR	39
Figure 15: RASR and subluxation ratio.....	40
Figure 16: Axis of rotation	45
Figure 17: 3D USI of vascular tissue	54
Figure 18: Side-by-side fusion imaging	55
Figure 19: Goniometer measurement of elbow at 90°	60
Figure 20: Positions of rotation included for USI analysis	61
Figure 21: Positions of forearm rotation and articular contact of the DRUJ	61
Figure 22: DRUJ bony landmarks seen dorsally in full supination.	62
Figure 23: DRUJ soft tissue landmarks: The 2 nd dorsal compartment	63
Figure 24: 4 th dorsal compartment	63

Figure 25: 5 th Dorsal compartment.....	64
Figure 26: 6 th Dorsal compartment.....	64
Figure 27: Anatomical compartments and extensor tendons	65
Figure 28: USI set up and DRUJ location	66
Figure 29: Ultrasound buttons used during image capture	67
Figure 30: Analysis of ultrasound image	68
Figure 31: Box plot diagrams	71
Figure 32: Non gripping (Static) forearm positions.....	72
Figure 33: Gripping (dynamic) forearm positions.....	73
Figure 34: Error bar graph.	76
Figure 35: Anatomic anomalies seen in supination using USI of the DRUJ.....	83
Figure 36: Anatomic anomalies seen in neutral using USI of the DRUJ	85
Figure 37: Anatomic anomalies seen in pronation using USI of the DRUJ.....	87

List of Tables

Table 1: Types of DRUJ surfaces and sigmoid notch found in cadaver wrist specimens.	20
Table 2: Grading of DRUJ displacement based on the Epicentre method a	37
Table 3: Summary of advantages of USI in the assessment of joints and surrounding structures	48
Table 4: Mean translation values and significance	71
Table 5: Within session repeatability analyses	74
Table 6: Inter-session repeatability analyses.....	75
Table 10: Current CT literature for assessing DRUJ kinematics	110

Attestation of Authorship

"I hereby declare that this submission is my own work and that, to the best of my knowledge and belief, it contains no material previously published or written by another person (except where explicitly defined in the acknowledgements), nor material which to a substantial extent has been submitted for the award of any other degree or diploma of a university or other institution of higher learning."

Acknowledgements

Special thanks must be made to several people and organisations whom made this thesis possible

To my primary supervisor Dr Wayne Hing, also to Mr Michael Boland for his extensive knowledge in the area of DRUJ biomechanics.

The New Zealand Association of Hand Therapists (NZAHT) and Auckland University of Technology (AUT) for the scholarships that I received

Delwyn Morisson at Horizon Radiology for all the help along the way

Dr Steve Taylor and Michael Steele for statistical analyses

My Colleagues Eileen Carroll, Jackie Chiplin and Edel Kelly for their ongoing support

My Husband James Oldfield for both his technology expertise and moral support

Abstract

The current study was conducted to establish normal values of Distal radioulnar joint (DRUJ) translation using ultrasound imaging (USI). Repeatability of quantifying DRUJ translation of the forearm in various positions using USI was additionally investigated. Lastly the data collected was compared to previously documented values established in the literature using Computerised Tomography (CT) imaging. It is fundamental to further clinical research in this area to ascertain the validity of using USI to quantify DRUJ translation in a normal population.

A cross-sectional reliability study was conducted with 23 normal participants. Ultrasound examination was conducted bilaterally on two separate occasions, using the Phillips iU22 diagnostic ultrasound machine. Static transverse images of maximal supination, neutral and maximal pronation, were taken three times. This process was repeated with the participant gripping a 1kg weight for the supination and pronation positions. Using the Sketchbook Express software programme, lines were drawn to assess the relative distance of known bony landmarks. This method is consistent with the rheumatoid arthritis subluxation ratio (RASR) described by Henmi et al. (2007). Statistical analyses of repeatability included a hierarchical mixed model method, analysis of variance (ANOVA) and Cronbach's alpha. Validity was also assessed comparing data to previously documented values in CT literature

Translation was found to occur in both non gripping supination and pronation compared with neutral ($p < 0.001$). There was statistically significantly more translation found with pronation (mean=1.69mm). Ulna radial translation in supination was found to occur to a lesser extent and in a volar direction compared with neutral (mean=0.67mm). Gripping pronation did not produce statistically significant changes compared to non gripping pronation. However, gripping supination was significantly higher ($p < 0.01$) in comparison to non gripping supination. Cronbach's alpha measurement for internal consistency was very high (0.9). Other than forearm position, there was no statistically significant difference between hand, left versus right, state or session. The RASR values in the current study demonstrated consistent measurements when compared to previously documented values.

This study demonstrated that USI can reliably detect translatory movement of the DRUJ in healthy participants. It supports the role of USI in future musculoskeletal applications and research. Alternative methods to accurately record translation may provide a less expensive and more accessible diagnostic tool in assessing DRUJ instability. This would reduce the dependence on CT or magnetic resonance imaging (MRI) scans to diagnose DRUJ instability in patients after trauma, inflammatory joint diseases or developmental disorders.

CHAPTER ONE - INTRODUCTION

The main role of the musculoskeletal system is to provide support for movement. The ability to examine musculoskeletal tissues both statically and under controlled movement is a significant advantage of musculoskeletal ultrasound imaging (USI) (McNally, 2011). Ligamentous injuries pose a challenge for traditional imaging modalities as they require a truly dynamic assessment (Jacobson, 2009). So far, USI has firmly established itself within this scope, with rapid, non invasive and high resolution assessment (Jacobson, 2009).

The number of musculoskeletal USI studies increased 200% from 1996 to 2006 particularly in professions outside radiography (Jacobson, 2009). For example the use of musculoskeletal USI increased by 42% among radiologists compared to other specialties, which demonstrated an increase in use of 12,025% (Jacobson, 2009). Higher utilisation of USI among other health professionals will inevitably expand the use of musculoskeletal ultrasound for imaging, and will impact on current reputable methods such as MRI and CT scans (Jacobson, 2009).

Instability is defined as an abnormal path of articular contact occurring during or at the end of the range of motion due to either alteration in joint surface orientation or deficiency of the main supporting ligaments (Ozer & Scheker, 2006). The aetiology of instability of the DRUJ is varied, stemming from trauma, inflammatory arthropathy or developmental and congenital disorders (Stuart, Berger, Linscheid, An, & Rochester, 2000). DRUJ dysfunction secondary to trauma is a common outcome and generally caused by disruption to the articular surface of the joint (Nathan & Schneider, 1991). Stability and normal articulation of the DRUJ depend on the topography of the joint surface, soft tissues in the triangular fibrocartilage complex (TFCC), DRUJ capsule and interosseous membrane (Moore et al., 2002). Instability of the DRUJ is associated with increased translatory motion of the ulna relative to the radius, due to failure of the stabilising anatomy (Garrigues, Sabesan, & Aldridge, 2008). Clinically, DRUJ instability is a painful condition limiting forearm movement, grip strength and the functional capacity of the patient.

Computerised tomography is currently considered the gold standard in assessing DRUJ translation and concurrent instability, although access and cost may be limiting factors (Lo, MacDermid, Bennett, Bogoch, & King, 2001). This study aims to establish if the use of USI is a reliable and valid tool for quantifying translation of the DRUJ of the forearm in both supination and pronation. To date there are no studies that have assessed in vivo translation of the DRUJ using USI. Alternative methods to accurately record translation may provide a less expensive and more accessible diagnostic tool in assessing DRUJ instability. This would reduce the dependence on CT or MRI scans to diagnose DRUJ instability in patients after trauma, inflammatory joint diseases or developmental disorders.

CHAPTER TWO – LITERATURE REVIEW

2.1 Background

The DRUJ is a complex joint that allows pronation and supination of the forearm. This has allowed important evolutionary changes to movement and function that allows high levels of functionality in the human hand (Nicolaidis, Hildreth, & Lichtman, 2000). The DRUJ is the distal articulation in the bi-articulate rotational arrangement of the forearm (Szabo, 2006). This joint allows the wrist and hand to be rotated from pronation to supination about a longitudinal axis that passes through the ulna fovea distally and radial head proximally (Linscheid, 1992). In addition, rotation of the forearm provides torque to the wrist and thus a unique ability to transfer rotational force to the grasping hand (Linscheid, 1992).

DRUJ instability can arise from variable mechanisms that can often be inter-related such as fractures, dislocations and soft tissue trauma (Jaffe, Chidgey, & LaStayo, 1996). Advanced rheumatoid, osteo and post-traumatic arthritis can also cause pathological instability in the DRUJ (Jaffe, et al., 1996). Current methods for analysing DRUJ instability have been reported in the literature with mixed evidence that effectively lack support. Yet, there is agreement that presently CT scanning is the gold standard in assessment of the DRUJ (Lo, et al., 2001).

2.2 Anatomy and Kinematics of the DRUJ and surrounding structures

The anatomy of DRUJ has been described to contribute toward joint stability through both intrinsic and extrinsic mechanisms (Tsai & Pakisma, 2009). Intrinsic stability is thought to arise from the triangular fibrocartilage (TFC), the palmar and dorsal radioulnar ligaments (PRUL & DRUL respectively), the DRUJ capsule, and the ulna collateral ligament (UCL) (Tsai & Pakisma, 2009). Extrinsic stability is achieved by contributions from both static and dynamic forces from the interosseous membrane, pronator quadratus (PQ) and the extensor carpi ulnaris (ECU) subsheath (Tsai & Pakisma, 2009).

The TFC is described as a triangular and almost semicircular fibrocartilagenous disc originating at the junction of the lunate fossa and sigmoid notch and inserting into the base of the ulna styloid (Mikic, 1989; Szabo, 2006). The insertion into the radius is fixed and firm whereas the ulna attachments are slightly lax and more ligamentous in nature (Mikic, 1989). This may be of functional significance as this loose attachment allows rotational movements of the ulna head to occur during pronation and supination (Mikic, 1989). The peripheral portion of the disc is heavier and stronger than the central portion, which is prone to perforation due to its thin nature (Mikic, 1989). The length of the disc is approximately 14-16mm and 9-11mm wide; it has a thickness of 4.5mm on the peripheral ulna margin and 2mm on the radial margin (Mikic, 1989). The central portion is more variable and can be between 0.5mm to 3mm (Mikic, 1989). The function of the disc is consistently described in the literature as comprising of two portions with specialised roles (Szabo, 2006). The central portion is designed for weight bearing and the peripheral portion is designed for tensile loading (Szabo, 2006). The TFC is stabilised by the ulna styloid along with the ECU subsheath and ulno-carpal ligaments (see Figure 1) and is commonly identified as the TFCC (Szabo, 2006). Thus the TFCC has three major functions, it bears 20% of the axial load of the wrist, stabilises the DRUJ and firms the ulnocarpal joint (Heuck, Bonel, Stabler, & Schmitt, 1997).

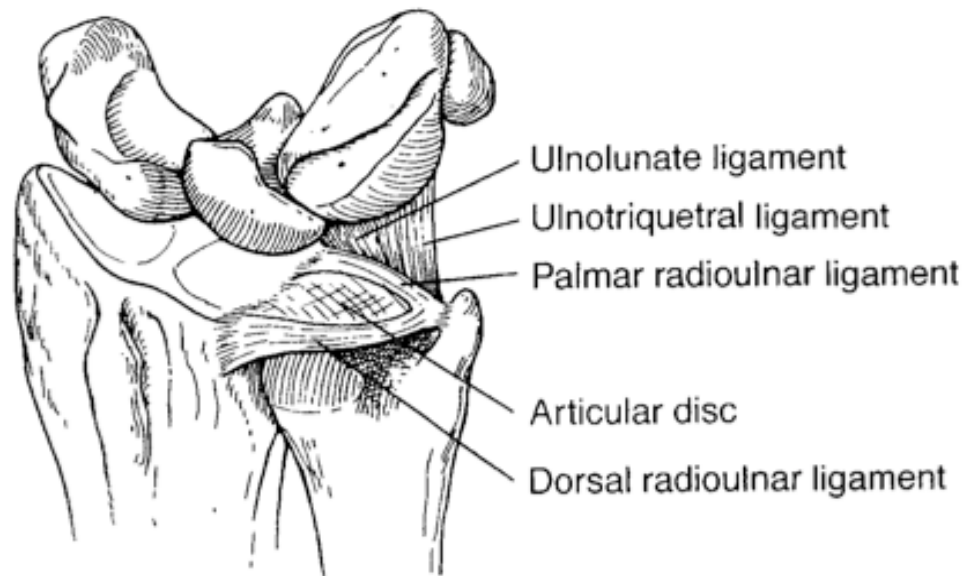


Figure 1: TFCC and supporting ligaments. Adapted from Nicolaidis, Hildreth & Lichtman (2000). Acute injuries of the distal radioulnar joint. *Hand Clinics*, 16, pp: 450.

The most important role of the TFC is to contribute to stability of the DRUJ, largely due to the peripheral portion of the disc, which is biomechanically suited to the role due to the thick, strong mechanical attachments to the radius and the ulna (Szabo, 2006).

A study investigating the contribution of the superficial and deep fibres of the TFCC, including the radioulnar ligaments, found that there was significant distal migration of the ulna only after both had been divided, rather than the superficial layer alone (Shen, Papadonikolakis, Garrett, Davis, & Ruch, 2005). Results from this study indicate that the deeper layer of the TFCC and DRUJ ligaments have a more stabilising role in longitudinal rather than transverse stability. Overall this study highlights the contribution of the TFCC to non pathological ulna variance and stability of DRUJ (Shen, et al., 2005).

There is variation in the current literature defining both the PRUL and DRUL. Szabo (2006) describes the ligaments as a thickening of the peripheral margins of the TFC disc composed of thick lamellar cartilage. Whereas, Tsai and Pakisma (2009) state that the ligaments arise also as part of the TFCC but are the palmar and dorsal deep fibres of the ligamentum subcruentum. Mikic (1989) describes the DRUJ ligaments as strengthened parts of the articular capsule that are firmly attached to the peripheral

margins of the disc, which are difficult to sharply separate and distinguish. More consistency associated with the function of the radioulnar ligaments currently exists within the literature. In a review of several studies, Szabo (2006) states that biomechanical evidence largely suggests that in pronation the DRUL must tighten to displace the ulna dorsally, and that the PRUL checks resultant forces to keep the joint reduced (Szabo, 2006). Furthermore, if this dynamic tensioning becomes disturbed, subluxation and dislocation may occur at the joint as a result (Szabo, 2006). Figures 2 and 3 show the function distal radioulnar ligaments during forearm rotation.

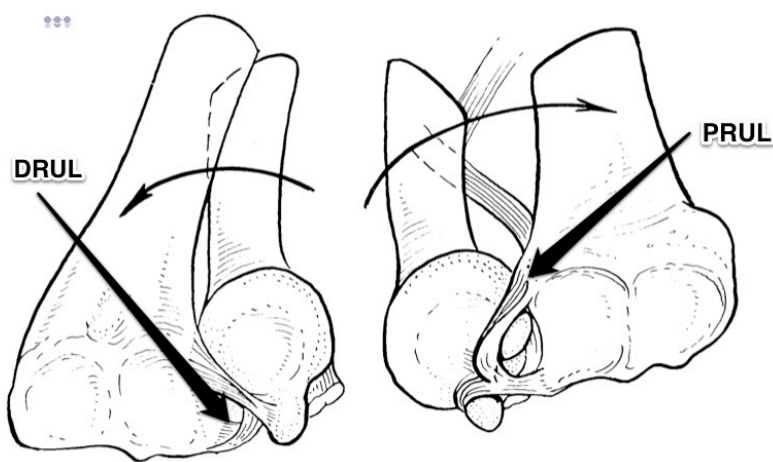


Figure 2: Functional role of the DRUJ ligaments. The first image on the left depicts the DRUL tightening with pronation as well as seating the ulna head against the sigmoid notch. On the right the opposite occurs with supination as the PRUL tightens and displaces the ulna head against the volar radial rim. Adapted from Linscheid (1992). Biomechanics of the distal radioulnar joint. *Clinical Orthopaedics and Related Research*, 275, pp: 53.

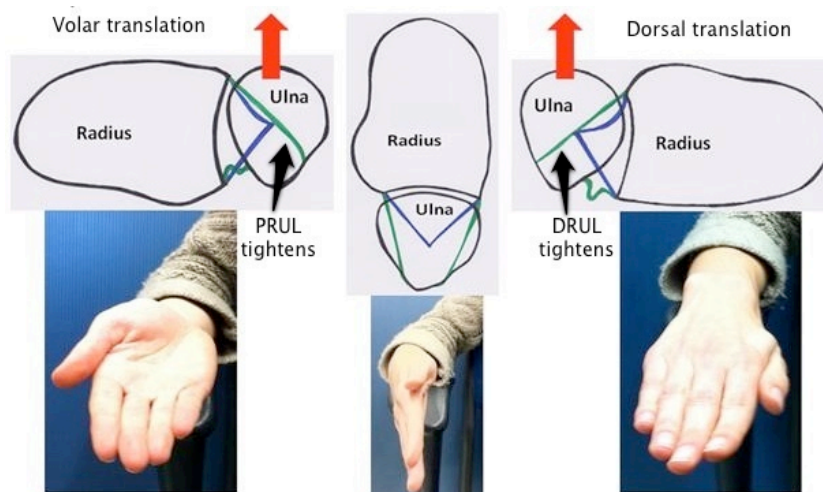


Figure 3: RUL's through rotation adapted from Wikipedia [Image]. (2012) Retrieved February 12th, 2012 from http://en.wikipedia.org/wiki/Triangular_fibrocartilage

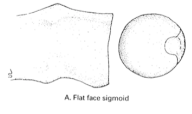
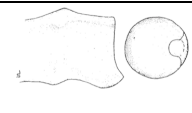


A study by Ward, Ambrose, Masson & Levaro (2000) confirms that the DRUL must tighten in pronation and that the equivalent occurs with the PRUL in supination. In this study the lengths of the radioulnar ligaments were measured simultaneously during forearm rotation (Ward, et al., 2000). Sensors designed to accurately determine small displacements in tissue length were attached to the ligaments in forearm neutral positions on 11 cadaver wrists. A change in position at the core of the sensor, was measured directly proportional to changes in length of the ligaments during manual forearm rotation of the specimens. The DRUL demonstrated progressively increased strain during forearm pronation as the PRUL simultaneously demonstrated decreased strain. The opposite occurred when the forearm was rotated into supination, where the PRUL was seen to increase strain while the DRUL decreased.

The barbs of the sensors used in this study were found to penetrate through both superficial and deep (also known as the ligamentum subcrucium) layers of the ligaments and showed no skewing during motion, which is thought to occur if these layers moved in an opposite motion confirming that both layers function synchronously (Ward, Ambrose, Masson, & Levaro, 2000). Earlier thoughts were that the deeper fibres or ligamentum subcrucium on the palmar aspect tightened with the dorsal superficial fibres during pronation and that the opposite occurred with supination (Kleinman, 2007). There is extensive debate in the literature regarding the role of the superficial and deep layers and generally there is no consensus to date on this topic and further investigation needs to be done.

There have been four cadaveric studies that have examined the importance of intrinsic stabilisers at the DRUJ (Stuart, et al., 2000; Tolat, Stanley, & Trail, 1996; Ward, et al., 2000; Watanabe et al., 2005). Three of these studies (Stuart, et al., 2000; Tolat, et al., 1996; Ward, et al., 2000) report the significant role of the PRUL in primary constraint of the DRUJ and the DRUL as a secondary constraint. Whereas Watanabe et al. (2005) examined the degree of contribution that the interosseous membrane demonstrated as an extrinsic stabiliser.

A study by Tolat et al. (1996) investigated the anatomy and relative stability of 50 cadaveric wrist specimens, specifically the DRUJ in both coronal and transverse planes. Analysis of DRUJ angles, ulna variance, sigmoid and ulna articular seats, PRUL angle and the palmar osteocartilagenous lip was conducted using photographs of the specimens harvested on one millimetre (mm) grid paper. The complex anatomy of the DRUJ is supported by the identification of three types of DRUJ angles in the mid-coronal plane and four types of sigmoid notch in the transverse plane, which can be matched in a matrix (Tolat, et al., 1996). Table 1 summarises the percentage of types of DRUJ observed with differing types of sigmoid notch.

Table 1: Types of DRUJ surfaces and sigmoid notch found in cadaver wrist specimens. Adapted from Tolat, Stanley & Trail (1996). *Journal of Hand Surgery*, 21, pp: 588-590.

Type of DRUJ Type of sigmoid notch	Image	1. Joint surface parallel	2. Joint surface: oblique	3. Joint surface: reverse oblique
A. Flat face notch		40%	60%	14%
B. Ski slope notch		18%	7%	14%
C. C-shaped notch		32%	20%	43%
D. S-shaped notch		10%	13%	29%

Although there was no statistical significance, a type A flat face sigmoid notch (the most inherently unstable) was most commonly seen in a type two oblique DRUJ and may suggest that this particular type of joint may have increased translatory motion compared to a more congruent C-shaped sigmoid notch (Tolat, et al., 1996). The importance of identifying anatomically variable DRUJ angles in cadaveric specimens may correlate with those reported radio-graphically and also explain variable axis of rotation, both reported in the literature (Tolat, et al., 1996). Results comparing the mean sigmoid notch angle and the ulna seat angle in the transverse plane show a differentiation of 60°:100° respectively. Furthermore, the mean radii of

both the sigmoid notch and ulna articular seat were found to be 19mm:10mm respectively. These results support a large body of literature suggesting that a significant amount of DRUJ motion is likely to be translational due to the relative incongruence of the articular surfaces and small appositional area (Tolat, et al., 1996). Lastly, the palmar osteocartilagenous lip, which was present in 98% of specimens, was shown to act like a buttress to palmar dislocation indicating an important stabilising role along with the PRUL, which attaches to it (Tolat, et al., 1996). In addition, the angle of the PRUL was greater (78°) in flat-faced sigmoid notch types than the mean of 68° seen across other types (Tolat, et al., 1996). This may suggest a greater stabilising 'check rein' function in the more unstable and incongruent Type A joints (Tolat, et al., 1996).

The importance of the PRUL has also been described by Stuart et al. (2000), after conducting a cadaveric study of DRUJ anatomical constraints. Both dorsal and palmar displacement of the radius relative to the ulna were measured in 16 specimens suspended in a custom built four axis testing machine (Stuart, et al., 2000). Each specimen was allocated to one of three fixed rotation groups of neutral rotation, 60° of pronation or 60° of supination. A fixed force of 67 newtons and translation limitation of 20mm were imposed as these values were found in pilot studies to avoid disruption to the intact soft tissues. Serial sectioning of the PRUL, DRUL, ulnocarpal ligament complex, ECU subsheath, and the distal and proximal portions of the interosseous membrane was conducted, after each, translation in both dorsal and palmar directions were measured. The PRUL was found to be the principal constraint to volar translation of the radius in all positions of forearm rotation. The DRUL contributed also to a lesser degree, but significantly more than the ulnocarpal ligament complex, ECU subsheath or the interosseous membrane. Dorsal displacement of the radius was found to be limited depending on the position of rotation of the forearm (Stuart, et al., 2000).

In forearm pronation the DRUL has been shown to contribute superior constraint compared with the PRUL and proximal interosseous membrane portion, during translation of the radius dorsally (Stuart, et al., 2000). However, the PRUL and proximal interosseous membrane did exhibit greater constraint than the distal interosseous membrane, ulnocarpal ligament complex and the ECU subsheath (Stuart,

et al., 2000). In forearm supination the PRUL and proximal interosseous membrane were found to contribute greatest constraint than the DRUL, which was also an essential constraint to dorsal displacement of the radius. Overall regardless of forearm rotation or wrist position the ulnocarpal complex and the ECU subsheath contributed marginally to either dorsal or volar translation (Stuart, et al., 2000).

However, the interosseous membrane is considerably influenced by the position of the forearm with the distal portion contributing to dorsal constraint more than volar, in forearm supination greater than pronation (Stuart, et al., 2000). Conversely, the proximal portion of the interosseous membrane constrains dorsal displacement more than volar and is more active during pronation than supination or neutral positions (Stuart, et al., 2000).

A limitation observed in this study was that translation was assessed purely in static positions rather than dynamic forearm rotation limiting functional relevance. This may have caused the role of the ECU subsheath to be downplayed by the results of the study, as it may not be active in the static forearm positions used in this study (Stuart, et al., 2000). Also this study indicated that the PRUL was dominant as a static restraint to both dorsal and volar translation of the radius relative to the fixed ulno-humeral joint (Stuart, et al., 2000). Clinically, a fall on an outstretched hand involves the limb to fix distally whilst the forearm and body rotates around it, which may limit the functional relevance of the study in this situation.

A similar earlier study by Kihara, Short, Werner, Fortino & Palmer (1995) found that when the interosseous membrane was disrupted first the DRUL was considered to be more important in stabilising the DRUJ in pronation and the opposite in supination with the PRUL acting as the prime stabiliser. Furthermore, the interosseous membrane and PQ were of equal importance as when any two of the four structures were divided the joint remained stable (Kihara, et al., 1995). The authors concluded that all four structures were equally responsible for stability at the DRUJ.

There is further agreement that both the PRUL and DRUL are crucial structures for joint stability at DRUJ. In a study by Ward et al. (2000), translational displacement was measured on 11 cadaver wrists with a linear variable displacement transducer, which was firmly attached perpendicular to the radius. Loads of 22.25 newtons were

applied via a load cell applicator and sensor. The DRUL, when excised in the absence of the articular disc, interosseous membrane and articular capsule was found to significantly increase dorsal translation of the radius relative to the ulna in all forearm positions particularly in forearm pronation. Similar findings were found in regards to the PRUL, preventing palmar instead of dorsal translation. The PRUL when excised led to significant increases in translation in all positions particularly supination. Overall it was found that these ligaments were important constraints in both volar and dorsal translation of the radius and that the DRUL was more important than the PRUL in dorsal dislocations of the radius relative to the ulna. Forearm range of movement was additionally measured and found that with excision of either half of the capsule to produce increases in range in both supination and pronation. Therefore this may suggest the capsule as an important guiding constraint to excessive pronation and supination (Ward, et al., 2000).

Another study conducted by Watanabe et al. (2005) further examined the role of the interosseous membrane rather than radioulnar ligaments in controlling translatory motion at the DRUJ. Although there were fewer specimens than previous studies (n=8), the study specifically looked at sectioning the interosseous membranes into three segments; the distal, middle and proximal segments (Watanabe, et al., 2005). As with the study conducted by Stuart et al (2000), both volar and dorsal translation was examined in static 60° pronation and supination, and neutral positions. It was found that after sectioning the distal portion of the interosseous membrane, dorsal displacement of the radius was more pronounced in neutral and supinated positions (Watanabe, et al., 2005). However, overall instability was noted mostly in the neutral and pronated positions with the middle and proximal portions having a slight contribution also. These results support those of Stuart et al. (2000) where it was found that after sectioning the interosseous membrane dorsal displacement was more affected than volar displacement. As opposed to the proximal portion which was only effective in pronated positions, it is suggested that the distal portion was the most restraining structure in the displacement of the radius volarly in pronation and dorsally in supination (Watanabe, et al., 2005). In addition, it is thought that the orientation and relative distances of the radial and ulna insertions of the interosseous membrane

fibres varied during forearm rotation and consequently tension of the different portions (Watanabe, et al., 2005).

The extrinsic stabilising mechanisms of the DRUJ is formed mostly by dynamic structures that are particularly active during end of range forearm rotation (Szabo, 2006). Muscular constraints including the ECU subsheath and PQ along with the interosseous membrane actively compress the ulna head into the sigmoid notch of the radius (Tsai & Pakisma, 2009). In addition, forearm flexors and extensors dynamically compress the DRUJ to enhance the stability across the joint (Tsai & Pakisma, 2009). PQ has a superficial head that is a prime mover of forearm pronation and the deep head which is utilised to constrain the DRUJ (Szabo, 2006). This function is particularly noticeable in pronation where the ulna head is actively stabilised into the sigmoid notch by the PQ, which conversely passively stabilises the joint in supination due to muscular visco-elastic forces (Szabo, 2006).

In summary the interosseous membrane plays several important roles in conferring stability of the DRUJ. This includes force transference from the radius and ulna, providing an origin for the extensor muscles, maintaining longitudinal forearm stability and providing stability for the DRUJ (Tsai & Pakisma, 2009). Motion at DRUJ is not purely axial, but combines sagittal translation with proximal to distal translation (Mackin et al., 2005). Rotational mobility of the wrist is possible in part to the TFCC but also the radioulnar ligaments (Mackin, et al., 2005). There has been much debate across the literature regarding the most important stabilising structures for the DRUJ. However, the majority of research has suggested that the radioulnar ligaments and joint capsule are important for stability in avoiding excessive pronation and supination. The function of the ligaments has also been extensively discussed with the PRUL preventing excessive volar translation, and the DRUL in dorsal translation.

2.2 Biomechanics of the DRUJ and surrounding structures

The semi cylindrical ulna head, which has a radius of curvature of 8° , is suspended into the sigmoid notch of the radius, a shallow concave curvature of approximately 15mm (Linscheid, 1992; Szabo, 2006). Full congruity between the DRUJ articulation is not possible due to the disproportion between the radius of curvature of the ulna and sigmoid notch (Szabo, 2006). Figures 4 and 5 demonstrate the congruity of the DRUJ, concave shape of the sigmoid notch and unique slope of the articular seat.

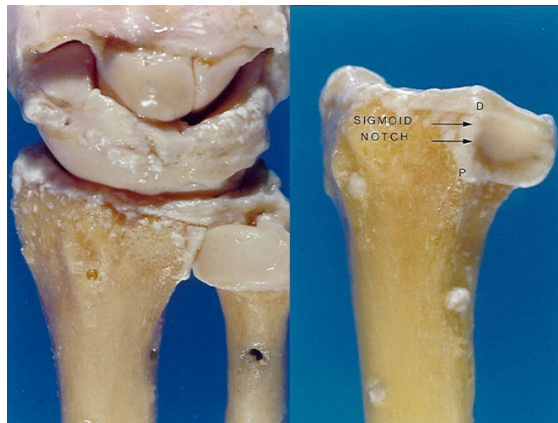

Figure 4: Cadaver sections of the DRUJ in relation to the radiocarpal joint and the sigmoid notch of the radius adapted from Verheyden, J.R & Gellman, H (2012). Retrieved 12th February 2012 from <http://emedicine.medscape.com/article/1240789-overview>

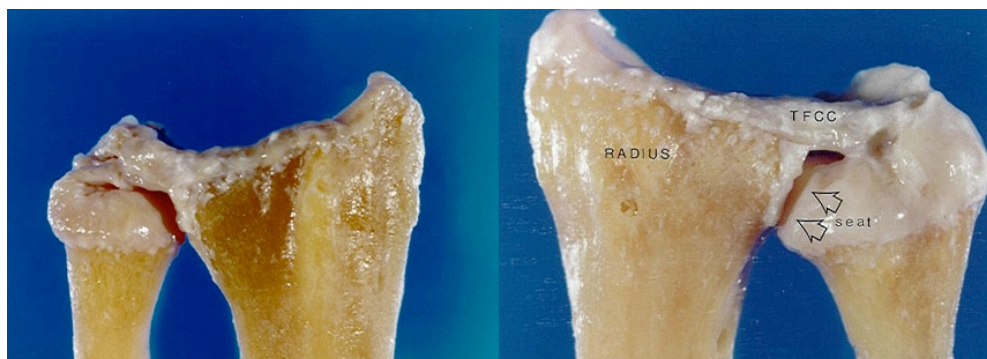


Figure 5: Cadaver sections showing the articular seat volarly then dorsally. Adapted from Verheyden, J.R & Gellman, H (2012). Retrieved 12th February 2012 from <http://emedicine.medscape.com/article/1240789-overview>

Subsequently, normal kinematic motion at the DRUJ causes a palmar translation in supination, and dorsal translation in pronation to allow for full rotation (Szabo, 2006). Also, translatory motion of the ulna head inside the sigmoid notch during pronation and supination can be described as a combination of sliding and rolling (Linscheid, 1992). The radius rotates in a near circular ellipse around its rotational centre, located at the radial head proximally and ulna head distally and thought to

occur from maximal supination to approximately 45° of pronation (T. Nakamura, Yabe, Horuichi, & Yamazaki, 1999; Tay et al., 2008). Subsequently in full pronation the radius is displaced volarly (T. Nakamura, et al., 1999). This may contribute to the axis of rotation shifting to a slightly more posterior position in maximal to 60° of supination compared to the axis found in 60° to maximal pronation (Tay, et al., 2008).

A major consequence that can take place during normal translation in pronation and supination is that the shear stress created across the narrow contact area within the DRUJ, may become pathological when a large external load is applied (Linscheid, 1992). Translatory motion permits less than ten percent of the ulna head to be in contact with the sigmoid notch and suggests stability arises heavily from connective tissue and soft tissue structures (Szabo, 2006). Several authors have reported quantifiable values and consistently state that there is approximately 2.8mm of translation dorsally and 5.4mm volarly, with a combined translation of 4-6mm (Szabo, 2006; Tsai & Pakisma, 2009). Although, in these reviews only Szabo (2006) specified that these values were recorded in neutral forearm rotation and differences in translatory motion for supination and pronation were not mentioned by any authors and may be different.

Supination is largely due to action of the biceps brachii and supinator in the proximal forearm, whereas pronation occurs distal to the mid-forearm due to pronator teres and PQ (Linscheid, 1992). Supinatory torque is normally 15% greater than pronatory torque causing not only rotational but translatory forces in all three planes rather than solely rotation (Linscheid, 1992). A recent review of the muscles influencing the DRUJ found that PQ generated the most force along the transverse axis and toward overall resultant forces, however brachialis contributed the most to reduction of forces along the transverse axis (Bader, Boland, Uhl, & Pienkowski, 2008). Biceps brachii was also indicated as an important muscle for reducing DRUJ forces along the shear axis and overall resultant forces, with brachialis contributing to a lesser extent (Bader, et al., 2008).

2.4 Pathophysiology

2.4.1 Distal radius fracture

Although traditionally distal radius fractures are associated with a high union rate, these injuries have a high complication rate (Jaffe, et al., 1996). Malunion is the most common complication after closed treatment of distal radius fractures and typically involves dorsal angulation, radial inclination and shortening of the distal radius (Moore, et al., 2002). Distal radius malunion can shift the normal axis of rotation, reduce joint congruity and limit forearm rotation (Moore, et al., 2002). Figure 6 demonstrates common deformities that can occur after distal radius fracture. Radial shortening has been reported to produce the greatest shift in the axis of rotation and more significantly, increase strain and distortion in the surrounding soft tissues including the TFCC (Adams, 1993). In fact, it is reported that distal radius fractures with more than 5mm of shortening have been associated with tearing of the distal radioulnar ligaments – known stabilisers of the DRUJ (Garrigues, et al., 2008).

Fractures that are associated with complete tears of the TFCC or ulna styloid fractures have a higher incidence of developing DRUJ instability (Lindau, Adlercreutz, & Aspenberg, 2000). A displaced fracture into the sigmoid notch and/or ulna styloid should raise suspicion for associated DRUJ instability and occasionally undiagnosed dislocation also known as a Galeazzi fracture (Jaffe, et al., 1996; Mulford & Axelrod, 2010). After a traumatic event, radiological evidence of positive ulna variance may represent a more severe injury including lesions to the TFCC and further investigation into the stability of the DRUJ should be considered (Shen, et al., 2005).

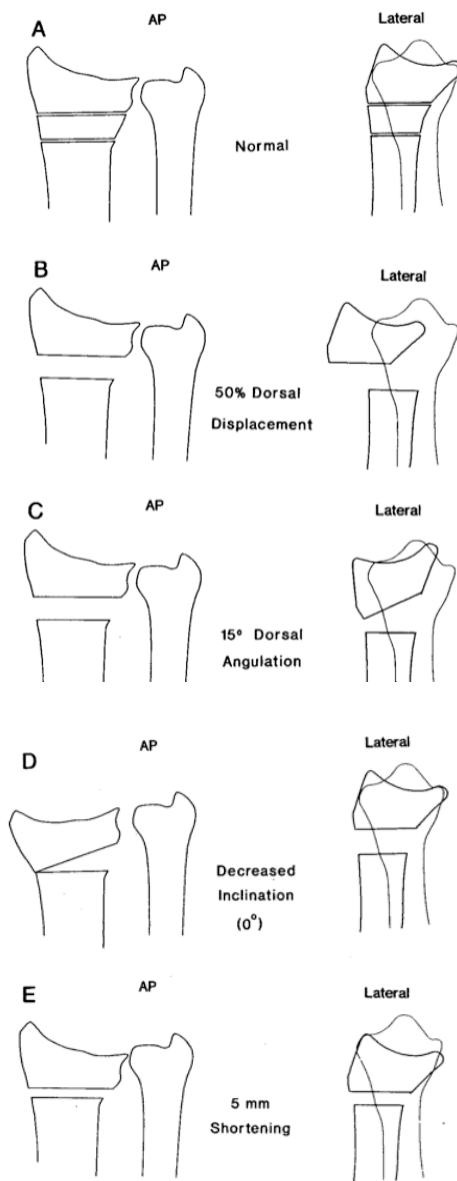


Figure 6: Radial deformities associated with DRUJ instability. From Adams (1993) *The Journal of Hand Surgery*, 18, pp: 493

2.4.3 Distal radioulnar joint dislocation

A dislocation of the DRUJ can occur in isolation but are more commonly associated with forearm fractures (Jaffe, et al., 1996). Dorsal dislocations are much more common than volar dislocation and involve high energy and forced hyperpronation injuries (Jaffe, et al., 1996). Dislocations can be classed as either simple or complex in nature with medical and surgical reduction corresponding to the difficulty their names suggest (Ozer & Scheker, 2006). Complex dislocations may be irreducible or easily subluxable, usually due to deficiency of the TFCC including the distal radioulnar ligaments (Ozer & Scheker, 2006).

2.4.4 Arthritis

Early Rheumatoid arthritis commonly involves the DRUJ and may cause ligament pathology and subsequent dorsal subluxation of the distal ulna (Jaffe, et al., 1996). This is due to a combination of synovitis within the joint itself, erosive bony changes, as well as destruction of the overlying extensor tendons (Jaffe, et al., 1996). Post-traumatic and osteoarthritic degeneration are also seen to a lesser extent at the DRUJ (Jaffe, et al., 1996)

Overall there are many pathological factors that can be attributable to the onset of DRUJ instability, highlighting the complexity of the joint itself and surrounding soft tissue structures. Acute injuries often occur simultaneously as seen with fracture-dislocations and soft tissue deficiency of the TFCC. This illustrates the importance for developing accessible and accurate diagnostic methods that can detect DRUJ dysfunction and instability before functional integrity is disturbed.

2.5 Current diagnostic methods

2.5.1 Radiography

X-rays of the DRUJ include postero-anterior views to assess ulna variance, or lateral views that can determine malalignment of the DRUJ (Burk, Karasick, & Wechsler, 1991). A prone postero-anterior view taken in 90° elbow flexion and 90° abduction of the humerus will be able to view the ulna styloid process directly opposite to the radius as well as the articulation between the radius and ulna (Burk, et al., 1991). Ulna variance can be measured using a variety of techniques that include drawing concentric circles or projecting a line from the ulna aspect of the articulating surface of the radius to the ulna (Burk, et al., 1991). Radial height of 10 -13mm is referred to in Figure 7 and an example of radiological analyses of ulna variance is shown in Figure 8. Positive ulna variance is concluded if the ulna projects distal to the most proximal line and reducing radial height in figure 8, dissecting the apex of the sigmoid notch, or conversely negative ulna variance if the ulna terminates proximal to this line and increased radial heights (Burk, et al., 1991). Detection of joint subluxation and dislocation of the ulna requires a neutral rotation lateral radiograph as even a slight degree of obliquity can result in pseudo-subluxation of the ulna (Burk, et al., 1991).




Figure 7: Radial height in mm. Singh, A.P. (2012). Retrieved 12th February 2012 from <http://boneandspine.com/category/fractures-dislocations/wrist-injuries>

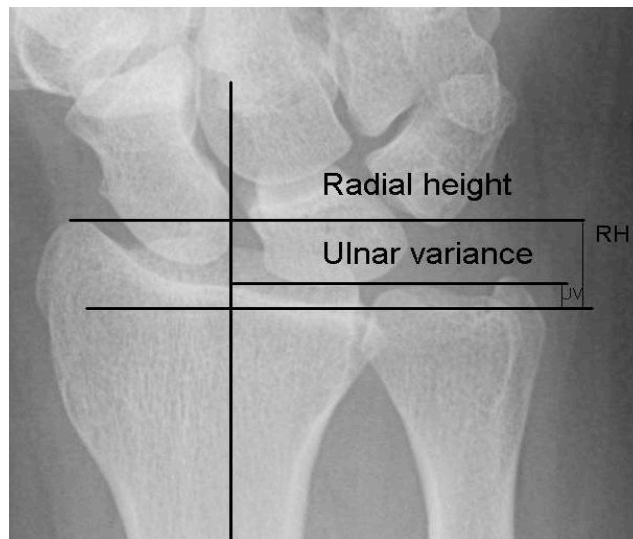


Figure 8: A radiological method for assessing ulna variance [image]. (2012). Retrieved January 10th, 2012 from <http://www.daliantrauma.com/new.asp?id=253747>

A study by Mino, Palmer & Levinsohn (1983) investigated radiological findings of joints that were confirmed as reduced, subluxed or dislocated, although there was no definition given for distinguishing between the three variations. The authors found that even 10° of rotation from the neutral position on the film, changed the radiographic relationship of the articulating surfaces of the DRUJ and carpal row. Dorsal dislocation was interpreted as subluxed, and subluxation reduced when 10° of supination from the neutral films were taken. Palmar dislocation could be determined however subluxation could not. Radiograph films with 10° of pronation from neutral dorsal dislocation were unable to be determined and subluxation appeared to be dislocated, whilst palmar subluxation appeared reduced and dislocation presented as merely subluxation (Mino, et al., 1983).

Wrist arthrography is another radiological method that may detect abnormal widening of the DRUJ, and can be seen on rotation from wrist pronation to supination (Burk, et al., 1991). A wrist arthrogram is performed with the patient in supine with extension of the elbow in full forearm pronation, and with the wrist flexed to 60° over a foam triangular block (Burk, et al., 1991). The DRUJ is then injected with 23-25 gauge needle to release an ionic contrast media into the joint space and lesions to the TFCC or radioulnar ligaments are depicted by defects in their surface or by contrast flow between two joint compartments that are normally separated (Burk, et al., 1991; Heuck, et al., 1997). This procedure may be more useful for detecting TFCC tears

rather than frank DRUJ instability, however a positive finding of a large TFCC tear may warrant further investigation into DRUJ stability, as it is a known risk factor for reduced stability (Burk, et al., 1991). A significant disadvantage of wrist arthrography is the invasive and painful nature of the procedure and further associated risks such as irritation, chemical synovitis and infection (Heuck, et al., 1997).

In summary, radiography can be useful in determining ulna variance but assessment of DRUJ stability remains complicated due to inconsistencies clinically with regards to patient positioning, which consequently affects the repeatability of interpreting x-ray films. True ulna variance and DRUJ congruency should be determined with the patient in prone with the elbow and shoulder flexed and abducted to 90° respectively. In addition, lateral views in true neutral rotation need to be ensured to obtain a valid measure of DRUJ stability (Mino, et al., 1983).

2.5.2 Magnetic resonance imaging

MRI can provide high resolution, direct images of the TFCC in axial, sagittal or oblique planes (Burk, et al., 1991). Patients are scanned in supine with the wrist pronated at the side (Burk, et al., 1991). MRI may be useful for diagnosing DRUJ subluxation and intercarpal ligament tears, however the TFC is the largest internal component of the wrist that can be imaged with a reported 90-95% accuracy in diagnosing tears (Burk, et al., 1991). The normal articular disc appears as a thick band of low signal intensity and, depending on position, have a particular shape – although the type of shape was not mentioned (Heuck, et al., 1997). In general, lesions or tears of the TFCC appear as discontinuations, irregularity and fragmentation of the low signal intensity band that represents the articular disc component (Heuck, et al., 1997).

MRI has been reported to have excellent sensitivity (1.0) and specificity (0.93) detecting TFCC lesions when compared with arthroscopy as a gold standard (Heuck, et al., 1997). Thin slice techniques are thought to provide a suitable spatial resolution achieved in standard MRI and may be most useful in the differentiation of partial and full thickness TFCC tears, with an accuracy of 95% in comparison to open surgery (Heuck, et al., 1997). However these authors only mention sensitivity and specificity scores, whereas likelihood ratios may be of more significance clinically as they also take into consideration true and false positive, true and false negative and prevalence

(Portney & Watkins, 1993). A current review regarding the accuracy MRI compared to wrist arthroscopy for detecting TFCC pathology in ulna sided wrist pain patients, found there was no consensus regarding use of this modality (Faber, Iordache, & Grewal, 2010). In fact, the authors suggest that monitoring of the presenting symptoms over time as incidental lesions and expected variations detected in MRI may increase unnecessary surgical procedures.

Estimating the size of the tears and classifying tears during dynamic MRI with simulated movement of the wrist may provide improved visualisation of the internal structures of the DRUJ in motion (Burk, et al., 1991). Unfortunately there are no studies that have investigated the validity of this particular method.

Major disadvantages associated with MRI are its higher cost, longer examination time (in comparison to USI) and difficulty obtaining high quality images in obese patients (Kijowski & De Smet, 2006). Furthermore, patients with implanted devices such as cardiac pacemakers and those who are claustrophobic are restricted from accessing MRI assessments (Kijowski & De Smet, 2006).

2.5.3 Computerised Tomography

CT scanning has been extensively investigated in the literature and remains the gold standard in assessing translatory motion of the DRUJ in a variety of forearm positions (Lo, et al., 2001). Furthermore it is efficient in delineating the cross sectional anatomy as the sigmoid notch and ulna head are easily viewed without overlapping of adjacent structures. This is especially useful when determining subluxation of the wrist and mal-rotation of the radius and ulna (Burk, et al., 1991; Heuck, et al., 1997). The ability to acquire multiple adjacent sections with high resolution in a relatively short time, to perform multi-planar image reconstruction, and to obtain additional information regarding the stability of soft tissue structures, has contributed to the popularity of CT amongst physicians (Heuck, et al., 1997). Many methods have been reported in the literature using a variety of bony landmarks viewed on CT images that can determine the relative translation of the radius about the ulna. There are six methods described to analyse data and bony markers that can provide data to determine the stability of the DRUJ. A summary of these studies and their main findings can be found in Appendix D.

1. The Radioulnar line (RUL) method shown in Figure 9 has been reported in four studies and is also termed the Mino criteria (Chiang, Chang, Lin, Liu, & Lo, 1998; Gong et al., 2009; Lo, et al., 2001; Mino, et al., 1983). The RUL method as described by Mino et al. (1983) uses the dorsal and ulna borders of sigmoid notch and the ulna head. Parallel lines are firstly constructed along both palmar and dorsal ulna and radial borders of the radius, secondly the ulna head is visualised and interpreted as reduced if it lies between these lines (Mino, et al., 1983). Palmar subluxation is determined when there is increased distance between the dorsal border of the sigmoid notch and ulna head (position c), and similarly dorsal subluxation when there is increased distance between the palmar lip of the sigmoid notch and the ulna head (position b) (Mino, et al., 1983). Dislocation (positions a and d) was also referred to in this study even though there was no definition of what factors were necessary for the joint to be interpreted as dislocated rather than subluxed. Although, normally the ulna does not remain centred in the sigmoid notch during rotation due to the normal translation that occurs during both supination and pronation (Szabo, 2006). In the study by Mino et al (1983) the ulna was found to translocate without migrating out of the confines of the sigmoid notch.

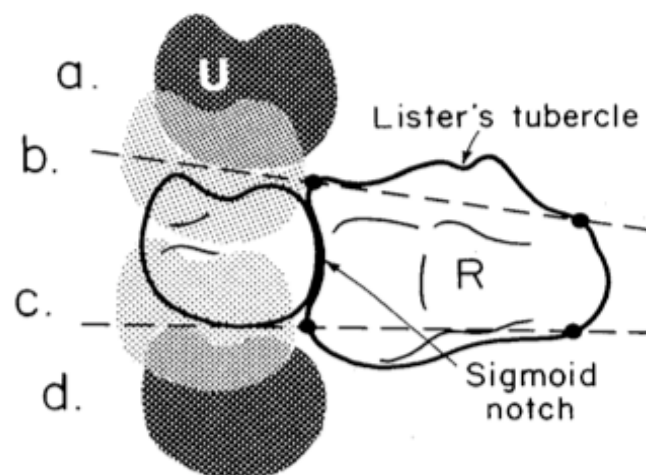


Figure 9: The original RUL or Mino method adapted from Mino, Palmer & Levinsohn (1983) *The Journal of Hand Surgery*, 8(1), 23-31

2. Equally, four studies have described a modified RUL method where a perpendicular line is added to connect the palmar (A) and dorsal (B) lip of the sigmoid notch (See Figure 10). The distance (C to D) of the ulna head lying palmar or dorsal to the palmar and dorsal margins is then calculated relative to the length of the sigmoid notch providing a ratio (CD/AB) to measure the amount of displacement (Henmi, Yonenobu, Akita, Kuroda, & Yoshida, 2007; Kim & Park, 2008; R. Nakamura, Horii, Imaeda, & Nakao, 1996; Park & Kim, 2008). A study by Park & Kim (2008) found that the mean RUL ratio in 45 asymptomatic wrists was 0.16 in pronation, 0.02 in neutral and -0.11 in supination. This method, unlike the original RUL method uses a quantifiable technique that does not rely on observer interpretation and therefore should be more accurate. There is also some reference to normal ratios that would be more useful clinically to compare a pathological population to, however larger studies should be done to establish these normal ratios in the literature (Park & Kim, 2008).

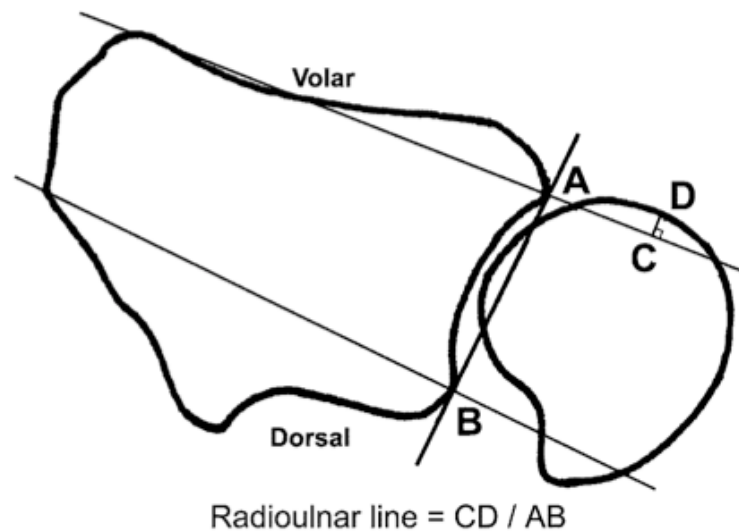


Figure 10: The modified RUL method adapted from Park & Kim (2008) *The Journal of Bone and Joint Surgery*, 90, 145-153.

3. The epicentre method has been described in five studies (Chiang, et al., 1998; Kim & Park, 2008; Lo, et al., 2001; R. Nakamura, et al., 1996; Park & Kim, 2008) and involves identifying the centre of rotation of the DRUJ and the chord of the sigmoid notch (See Figures 11 and 12). The halfway point between centre of the ulna styloid process and the centre of the ulna head is thought to give rise to the centre of rotation (Chiang, et al., 1998; Kim & Park, 2008; Lo, et al., 2001; Park & Kim, 2008). The ventro-medial and dorso-medial borders of the sigmoid notch are identified and a line is drawn to connect the two points and form the chord of the sigmoid notch (AB) (Chiang, et al., 1998; Lo, et al., 2001). In addition, two of the studies reporting this method measured the distance of the chord (AB) of the sigmoid notch (Kim & Park, 2008; Park & Kim, 2008). A perpendicular line is then drawn from the centre of rotation to the midpoint of the chord of the sigmoid notch (D) (Chiang, et al., 1998; Kim & Park, 2008; Lo, et al., 2001; R. Nakamura, et al., 1996; Park & Kim, 2008).

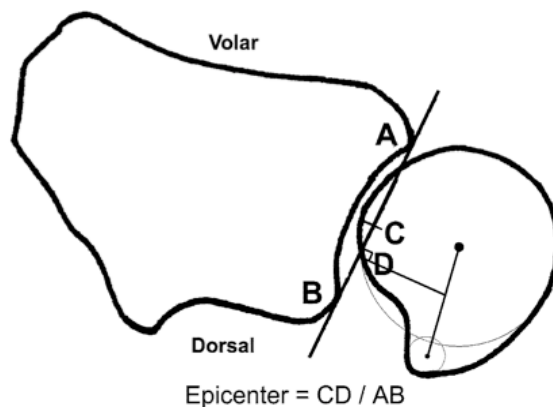


Figure 11: Ratio Epicentre method. Adapted from Park & Kim (2008). *The Journal of Bone and Joint Surgery*, 90, pp: 150

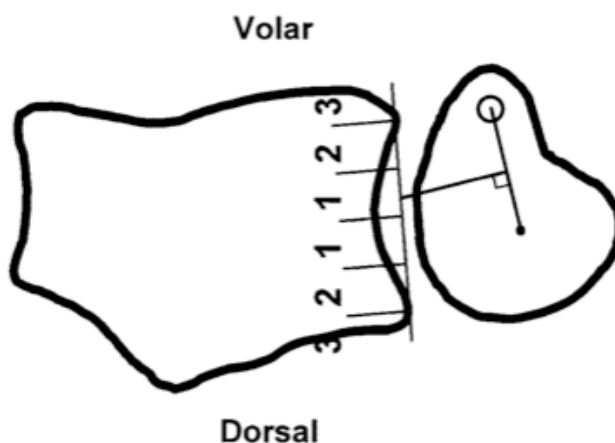


Figure 12: Graded Epicentre method. Adapted from Lo et al (2001). *The Journal of Hand Surgery*, 26, pp: 239.

Translation is then measured on a graded system where dorsal displacement from the midpoint of the sigmoid notch is positive and volar displacement is negative (Park & Kim, 2008). Table 2 summarises the grading system used in the epicentre method. A displacement greater than 25% is considered as severe subluxation or dislocation (Kim & Park, 2008; Lo, et al., 2001). The DRUJ is considered normal if the perpendicular line lies in the middle of the sigmoid notch (Chiang, et al., 1998; Kim & Park, 2008; Lo, et al., 2001; R. Nakamura, et al., 1996; Park & Kim, 2008). Similar to the radioulnar line method, the epicentre method places modest consideration to normal DRUJ kinematic where the ulna head does not stay centred in the sigmoid notch with pronation and supination.

Table 2: Grading of DRUJ displacement based on the Epicentre method adapted from Chiang et al (1998). *Chinese Medical Journal*, 61, pp: 711.

Grade	Position of the centre of rotation perpendicular line relative to the sigmoid notch	Displacement
1	Within middle half of the sigmoid chord	Normal
2	Outer half of the sigmoid notch	Mild subluxation
3	Outside the sigmoid notch	Severe subluxation or dislocation

4. The congruency method shown in Figure 13, has been reported in three studies (Chiang, et al., 1998; Lo, et al., 2001; R. Nakamura, et al., 1996) and involves subjectively assessing the congruency of the arcs made by the ulna head (C1) and the sigmoid notch (C) (Lo, et al., 2001). The DRUJ can be concluded as congruous or non-congruous by comparing the two arcs (Chiang, et al., 1998). A study by Nakamura et al (1996) also described the modified congruity method, which primarily consisted of considering dorsal displacement in pronation as normal. However, there was no discussion within the study pertaining to the rationale of the modified method as opposed to the original congruity method.

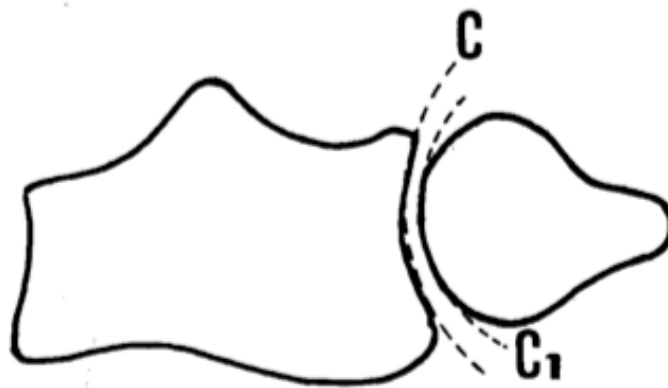

Figure 13: The congruity method. Adapted from Chiang et al (1998). *Chinese Medical Journal*, 61, pp: 711.

5. The radioulnar ratio (RUR) method shown in Figure 14 was developed by Lo et al (2001), as the authors believed that the previously mentioned RUL, epicentre and congruity methods lack accuracy in diagnosing DRUJ instability (Lo, et al., 2001). There have been three studies that have reported the RUR method. Firstly, identify the centre of the ulna head using a transparent plastic template marked with concentric circles of increasing radii (Kim & Park, 2008; Lo, et al., 2001; Park & Kim, 2008). The largest circle of the template is positioned within the sclerotic rim of the ulna head and the centre point marked on the ulna (Lo, et al., 2001). A line is then drawn to connect the dorsal and volar aspects of the sigmoid notch similarly to the epicentre method forming the line AB (Lo, et al., 2001). A perpendicular line is then drawn from the centre of the ulna head (CD) to the AB line of the sigmoid notch (Kim & Park, 2008; Lo, et al., 2001; Park & Kim, 2008). The length of line AD is measured and divided by the length of the line AB (Kim & Park, 2008; Lo, et al., 2001; Park & Kim, 2008). Values more or less than the mean value of the uninjured contralateral wrist more than or equal to two standard deviations were defined as subluxed (Kim & Park, 2008).

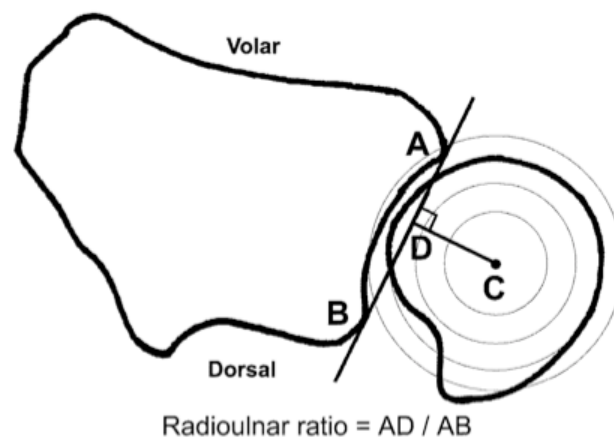
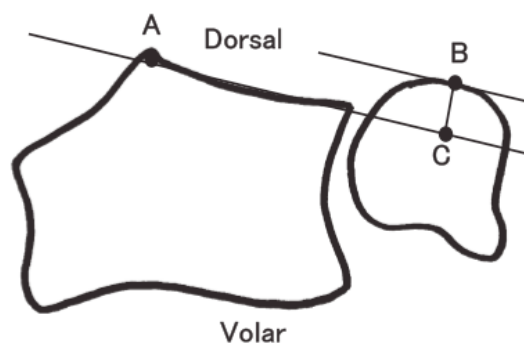


Figure 14: The RUR developed by Lo et al (2001). *The Journal of Hand Surgery*, 26, pp: 239 adapted from Park & Kim (2008). *The Journal of Bone and Joint Surgery*, 90, pp: 150

6. The rheumatoid arthritis subluxation ratio (RASR) has been described by Henmi et al. (2007), as an alternative method for assessing DRUJ subluxation in a rheumatoid arthritis population (See Figure 15). Sigmoid notch scalloping, ulna head erosion and development of a volar shelf in rheumatoid patients may cause the other methods of assessment to be difficult to apply as they rely on intact bony structures (Henmi, et al., 2007). To find the RASR a line is drawn tangential on the dorsal surface of the distal radius from the Lister's tubercle (point A) to the ulna aspect of the distal radius (Henmi, et al., 2007). Next, a line is drawn parallel to the first line passing on the dorsal ulna (point B) and perpendicular line then connects the two parallel lines previously drawn (BC). The RASR is found by dividing lines BC by the line AC (Henmi, et al., 2007). The greater the RASR, the greater dorsal subluxation is considered present at the DRUJ (Henmi, et al., 2007). Park & Kim (2008) developed a subluxation ratio that differed slightly and involves drawing two lines perpendicular to a line connecting the dorsal and volar margins of the sigmoid notch. The ratio of the length of the lines CD to AB is calculated.

A)



B)

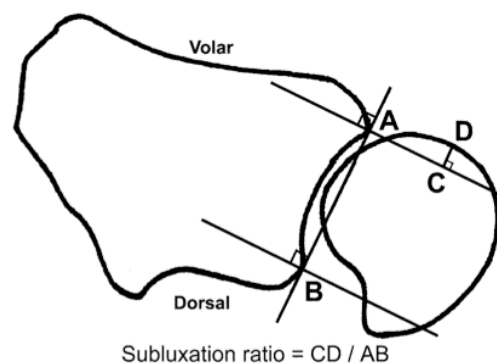


Figure 15: RASR and subluxation ratio. Adapted from (A) Henmi et al (2007). *Modern Rheumatology*, 17, pp: 280 & (B) Park & Kim (2008). *The Journal of Bone and Joint Surgery*, 90, pp: 150

Lastly, a study by Tay, Berger, Tomita, Amrami & An (2007) did not use any of the methods previously described but investigated in vivo 3-Dimensional (3D) CT images of the DRUJ during resisted rotational torque. CT images were analysed with the ulna fovea as a bone marker against an x-y-z transformation matrix (Tay, et al., 2007).

Overall, the sigmoid notch is identified in all five methods for analysing cross sectional CT images of the DRUJ. The RUL, epicentre and RUR methods construct lines connecting the volar and dorsal margins of the sigmoid notch, whilst the congruity method uses the entire contour of the notch as a reference point. The RASR uses the dorsal margin of the sigmoid notch as rheumatoid arthritis patients often develop a volar shelf (Henmi, et al., 2007). The ulna head is identified in all five methods, although each method applies an alternative technique to identify displacement relative to the radius. The entire ulna head is identified in the RUL method, whereas both the epicentre and RUR methods identify the centre of the ulna head. Furthermore, the epicentre method additionally uses this landmark to find the centre of rotation by finding the halfway mark between the ulna styloid and centre of the ulna head. The congruity method uses the contour of the ulna head relative to the sigmoid notch and lastly the RASR uses the dorsal margin of the ulna head. One other method used only the ulna fovea plotted against an x-y-z 3-dimensional matrix (Tay, et al., 2007). Clinically, the RUL and RASR methods seem the least complex and most consistent methods to use. There could be inconsistencies with some other methods that rely on observer interpretation and identifying the centre of the ulna head due to changes in the centre of rotation depending on the positioning of the elbow and also during pronation and supination (Fu et al., 2009; Tay, et al., 2008).

There is a large variation reported in the literature regarding the position during the CT scanning procedure, not only pronation or supination of the forearm, but also the elbow and shoulder. Only two studies have reported the position of the shoulder when obtaining CT images of the DRUJ (Henmi, et al., 2007; Kim & Park, 2008). A study by Kim & Park (2008) stated that the shoulder was in an adducted position, whereas Henmi et al (2007) described participants in a prone position with their shoulder elevated above the head. The recommended position of the shoulder when taking views of the DRUJ is in 90° of abduction and neutral rotation (Fu, et al., 2009).

Elbow position has been reported in three studies and is more consistently described than shoulder positioning (Kim & Park, 2008; Lo, et al., 2001; Park & Kim, 2008). The elbow was positioned at 90° of flexion in two in vivo studies that compared several of the CT methods for assessing DRUJ translation (Kim & Park, 2008; Park & Kim, 2008). In the study by Kim & Park (2008) CT images of RUL, epicentre and RUR methods were compared with clinical findings after distal radius fracture. Park & Kim (2008) investigated inter and intra-observer repeatability of the three methods previously described but also included the subluxation ratio. Lastly, a study by Lo et al. (2001) examined sequential division of the DRUJ stabilising structures in cadaver specimens and obtained CT images of translation after each division. The elbow was fixed in a custom made device at 90° of flexion. The effect of the position of both the elbow and forearm when assessing DRUJ kinematics has shown that there is widespread variability in distal to proximal translation (Fu, et al., 2009). Proximal translation of the radius was found to be greatest with the elbow at 90° and the forearm in mid pronation. The least distal to proximal translation occurred at 45° of elbow flexion with the centre of rotation shifting palmarly and ulnarly with increasing elbow extension (Fu, et al., 2009).

The position of pronation and supination when obtaining CT images of the DRUJ is also significantly variable across nine studies (Chiang, et al., 1998; Henmi, et al., 2007; Kim & Park, 2008; King, McMurty, Rubenstein, & Ogston, 1986; Lo, et al., 2001; Mino, et al., 1983; Park & Kim, 2008; Pirela-Cruz, Goll, Klug, & Windler, 1991; Tay, et al., 2007). Maximal pronation and supination were used in three studies (Chiang, et al., 1998; Lo, et al., 2001; Tay, et al., 2007). Lo et al. (2001) investigated the repeatability of the RUR method of analysis compared with three other methods including RUL, epicentre and congruity, although the congruity method was omitted early in the study due to exceedingly weak repeatability. CT images were obtained in four stages, firstly in a normal patient population followed by evaluation of cadaver specimens in stage two. Stage three also investigated cadaver specimens but images were taken after sequential division of known stabilising structures and lastly stage four, evaluation of a rheumatoid arthritis population was conducted using the same methods as stage one (Lo, et al., 2001). Tay et al. (2007) found that in normal participants full isometric pronation the ulna fovea was displaced by 3.09mm and in

full isometric supination 2.17mm. Dorsal displacement of the ulna fovea was seen in pronation to occur 0.13mm and palmar displacement in supination, which measured 0.51mm. In addition, ulna variance was shown to change as Z component (longitudinal) measurements differed in full isometric pronation versus supination. In maximal isometric pronation the ulna fovea displaced 0.23mm in a disto-proximal direction, and in supination 0.44mm and therefore ulna variance was shown to increase in both positions but mostly in supination (Tay, et al., 2007).

Sensitivity, specificity, positive predictive value (PPV) and negative predictive value (NPV) of DRUJ instability have been investigated in RUL, epicentre and congruity methods to gage the clinical application and accuracy of these methods (Chiang, et al., 1998). Each method was measured in neutral, full supination and full pronation and found that the epicentre method was superior overall particularly in regards to specificity (Chiang, et al., 1998). The RUL method showed very high sensitivity (100%) and specificity (100%) but average PPV (43.2%) and NPV (44.7%) whereas the epicentre method had slightly lower sensitivity (82.4%) and specificity (94.6%) but higher PPV (87.5%) and NPV (92.1%) indicating that the epicentre method may be more useful (Chiang, et al., 1998). The congruity method yielded the lowest sensitivity (76.4%) and specificity (59.5%) although had a much higher NPV (84.6%) and slightly higher PPV (46.4%) than the RUL method (Chiang, et al., 1998). These results did not give any indication of which method may be more useful clinically. The inclusion of a likelihood ratio may have provided more detail regarding which method would be of benefit in a clinical setting (Portney & Watkins, 1993).

A study investigating only full maximal pronation was conducted to compare the RASR with the modified RUL and also correlated findings with extensor tendon rupture in a rheumatoid arthritis population (Henmi, et al., 2007). The ratio's calculated using the RASR were found to be higher in rheumatoid arthritis patients (0.376) compared to healthy volunteers (0.106) and in addition the tendon rupture group (0.444) were also significantly higher than the non-tendon rupture group (0.333) (Kim & Park, 2008).

Pronation and supination at 70° has been used as the position of choice for CT scanning in two studies (Kim & Park, 2008; Park & Kim, 2008). CT images of DRUJ instability in these positions demonstrated that after distal radius fracture, residual

deformities including dorsal tilt influenced translation although did not correlate well with clinical examination of dorsal and volar translation of the ulna (Kim & Park, 2008). A study by Park & Kim (2008) showed significant discrepancies of DRUJ translation between the RUL, epicentre, RUR and RASR methods in 70° pronation, supination and in neutral but mostly reported on intra and inter-observer repeatability for the four methods.

There were two studies that used neutral rotation and four different positions of forearm rotation including full pronation, 45° of pronation, full supination and 45° of supination (King, McMurty, Rubenstein, & Ogston, 1986; Mino, et al., 1983). King et al. (1986) demonstrated significantly greater translation of the ulna in full supination and pronation compared with 45° supination and pronation particularly with palmar subluxation. Using the RUL method a reduced DRUJ was able to interpret in all rotation positions, as was progressive palmar and dorsal dislocation (King, McMurty, Rubenstein, & Ogston, 1986; Mino, et al., 1983).

Only one study investigated translation in neutral forearm position without assessing the effect of different positions of forearm rotation and found that normal translation occurring with palmar stress is 2.1mm compared with dorsal stress of 1mm (Pirela-Cruz, et al., 1991). Clinically this study may not be useful as forearm neutral is considered the most inherently stable position, and often instabilities are seen in mid to full supination and pronation during functional tasks (Mackin, et al., 2005).

There has been extensive debate amongst authors regarding the repeatability of methods for assessing translation in CT images for both normal and disease specific populations (Chiang, et al., 1998; Henmi, et al., 2007; Kim & Park, 2008; King, McMurty, Rubenstein, & Gertzbein, 1986; Lo, et al., 2001; Mino, et al., 1983; Park & Kim, 2008; Pirela-Cruz, et al., 1991; Tay, et al., 2007). One study modified the RUL and congruity methods as the original methods were thought to produce a large percentage of false positives and consequently reduce repeatability (R. Nakamura, et al., 1996). The authors found that the percentage of false positives reduced to equal the epicentre method although recommended the modified RUL method due to a more simplified application with high sensitivity and specificity values. The RUR method was found to be equivocal to the epicentre method in identifying individuals

with normal DRUJ translation (Lo, et al., 2001). Although, when identifying subluxation in an abnormal population, the RUR was found to be superior with high intra and inter observer repeatability (Lo, et al., 2001). Additionally, this method was able to detect subluxation earlier when stabilising structures were sequentially divided (Lo, et al., 2001). Lastly the RASR was investigated as the other methods previously described may not be applicable to a rheumatoid arthritis (RA) population due to erosion of the ulna head (Henmi, et al., 2007). The RASR was found to have a much higher sensitivity in an RA population compared to the modified RUL method. (Henmi, et al., 2007).

The variation in values of translation and repeatability across the current methods of CT analysis may be dependant on the use of certain bony landmarks that may exhibit anatomical anomalies. It has been seen in an anatomical study by Tolat et al. (1996) that the sigmoid notch and opposing joint surfaces of the DRUJ can exhibit different shapes that may affect distances and angles calculated in methods such as the modified RUL, epicentre, RUR, congruity and RASR methods. Furthermore methods that rely on identifying the centre of rotation through the ulna may be methodologically flawed as the axis of rotation has been found to move from the radial to ulna aspect of the DRUJ as the forearm rotates from pronation to supination (Tay, et al., 2008), and therefore may not be an accurate landmark depending on the position of rotation of the forearm (See Figure 16).

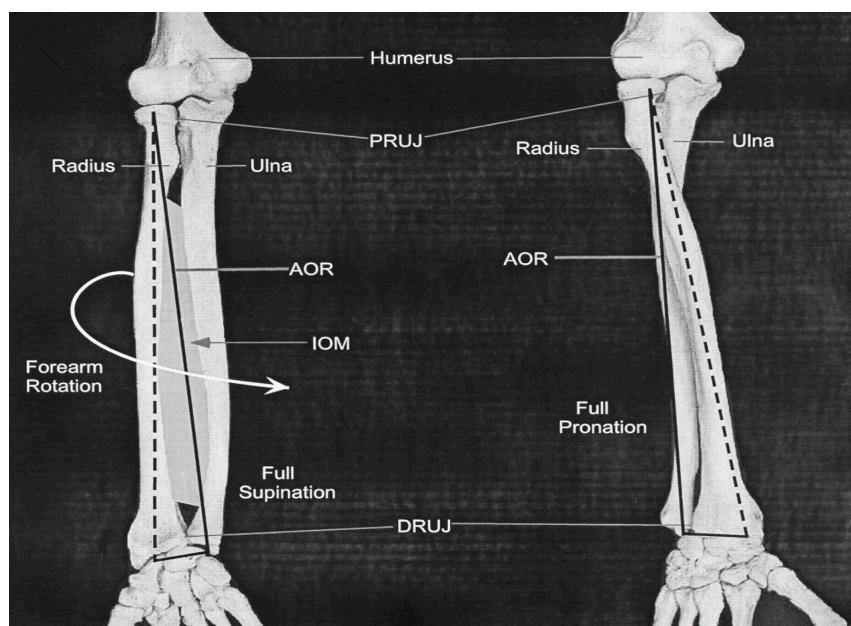


Figure 16: Axis of rotation shifting in full supination compared with full pronation. Adapted from Tynan, et al, (2000), *The Journal of Bone and Joint Surgery*, 82, pp: 1727.

2.5.4 Ultrasound Imaging

Ultrasound Imaging is becoming accepted as a highly capable and efficient method for evaluating the musculoskeletal system (Bianchi, Martinoli, Sureda, & Rizzatto, 2001). The development of high resolution transducers and high frequency probes with near field focusing has increased the accuracy in assessment of superficial anatomic structures (Adler, 1999; Bianchi, et al., 2001). USI provides a relatively inexpensive and rapid evaluation of the wrist and hand, and works well when associated with standard radiographs in the diagnosis of pathological hand injuries and diseases (Bianchi, et al., 2001). Significant advances in these areas combined with the positive economic factors has renewed interest in USI as a diagnostic tool (Adler, 1999). Although some clinicians are unfamiliar with the images produced by ultrasound, many are integrating the modality into their daily practice, which is practical given the portability of some ultrasound units compared with other modalities (Lento & Primack, 2008).

Diagnostic USI gives the clinician the opportunity to interact with the patient, who can direct the examination toward the symptomatic area (Lento & Primack, 2008). Whilst MRI does have the advantage of examining a large area, it may detect several abnormalities or anomalies that may be clinically irrelevant (Lento & Primack, 2008). USI enables the clinician to focus the assessment to the most relevant area (Lento & Primack, 2008). Furthermore, there is the significant advantage of being a dynamic study with the symptomatic area being imaged in real time, and the ability to compare this with the asymptomatic side or area if accessible (Lento & Primack, 2008). The ability to assess pathological movement of tendon, bursa, muscles and joints in real time enables the patient to provide feedback and vital information to the examiner, which may reveal tendon subluxation, joint subluxation or ligamentous incompetence (Lento & Primack, 2008). More recently, USI has been shown to effectively measure neural excursion during different nerve mobilisation exercises (Ellis, Hing, & McNair, 2012). Overall, USI is useful in the examination of a variety of musculoskeletal tissues with significant diagnostic and clinical implications.

The diagnostic capabilities of non-dynamic and dynamic USI have been well documented in the shoulder and elbow joints, and to some extent in the hand. The stability of the Glenohumeral joint (GHJ) has been investigated using USI, in particular

the presence of Labral tears and Hills-Sachs deformities (Kijowski & De Smet, 2006). USI, when compared to MRI, was found to have a sensitivity of 88-95% and specificity of 67-100% in the detection of Labral tears (Kijowski & De Smet, 2006). In addition it was found that USI had a sensitivity of 91-100% and specificity of 89-100% for Hills-Sachs deformities (Kijowski & De Smet, 2006). The same authors mention the Acromioclavicular joint (ACJ), where USI is thought to identify joint space widening and thickening of the joint capsule and adjacent ligaments (Kijowski & De Smet, 2006). Dynamically, adduction of the arm is useful to assess for ACJ incompetence (Jacobson, 2009). In addition, USI of the ACJ can directly measure the distance from the coronoid to the acromion, in stressed and unstressed joints, in conjunction with assessing the success of reduction techniques (Wang, Chhem, Cardinal, & Cho, 1999). Examination of external rotation of the shoulder has been shown to evaluate biceps brachii tendon dislocation and elevation of the arm for rotator cuff impingement and adhesive capsulitis (Jacobson, 2009). In the elbow, ulna nerve subluxation and snapping Tricep syndromes has been demonstrated using USI whilst the participant actively flexes the elbow (Jacobson, 2009). Lastly flexion of the finger can be used to evaluate for boxers knuckle at the Metacarpophalangeal joint (MCPJ), identifying potential extensor hood injuries or extensor tendon subluxation (Jacobson, 2009).

Dynamic examination facilitates the diagnosis of some ligamentous pathologies when a stress manoeuvre is applied to a particular joint as seen with tears of the thumb UCL, which may show increased mobility of the MCPJ joint (Bianchi, et al., 2001). In patients with acute and chronic UCL injuries of the elbow, dynamic imaging may demonstrate simultaneous ligament laxity with asymmetric widening of the medial joint space (Kijowski & De Smet, 2006). USI also provides good visualisation of the scapholunate ligament at rest and under dynamic stress and similar concepts could be applied to the DRUJ (McNally, 2011).

Wang et al. (1999) suggests that the many advantages of USI over MRI should warrant its wider use particularly as a first line investigation. The authors suggest that USI remains under-utilised where joint abnormalities are concerned, as MRI remains the pre-eminent modality worldwide for its ability to depict anatomic structures and relationships (Wang, et al., 1999). Table 3 summarises the many advantages that USI has over MRI.

Table 3: Summary of advantages of USI in the assessment of joints and surrounding structures. Adapted from Wang et al (1999) *Radiologic Clinics of North America*, 37, pp: 653-668

More widely available and comparatively cheaper
Real time imaging
Dynamic assessment possible
No sedation of children or claustrophobic individuals necessary
Portable and mobile
Easy and rapid side to side comparison
Better characterisation of fluid
Modality of choice for non opaque foreign bodies

To date there is little evidence examining the role of USI in detecting joint subluxation at the wrist, in particular at the DRUJ. Kijowski & De Smet (2006), state that whilst USI is superior to MRI in that it produces higher resolution imaging of superficial structures, a major disadvantage is the limited field of view and lack of assessment of deeper soft tissue structures and bones.

There is some support in regards to the use of USI in the detection of small joint effusions, a known indication of underlying joint pathology (Lento & Primack, 2008). USI may also provide further information about some joint pathologies, particularly inflammatory or infective arthritis where colour or power Doppler can detect a simultaneous increase in blood flow to the joint synovium (Lento & Primack, 2008). There is debate as to whether USI can accurately diagnose TFCC and other ligamentous pathologies in the wrist. Bianchi et al. (2001) state that despite USI being useful for diagnosing a large variety of pathological conditions of the wrist and hand, CT, MRI or CT and MR-arthrography is needed for proper evaluation of structures such as the TFCC and carpal ligaments. Furthermore, the limited sonographic access and spatial

resolution does not provide enough information on the internal structure of the TFCC to allow a final diagnosis (Heuck, et al., 1997). Lento & Primack, (2008) are in agreement, although discuss that whilst USI cannot penetrate into the joint directly to visualise cartilaginous injuries there are secondary signs that may alert to an underlying injury. Cysts in particular are most commonly located on the lateral joint line, appearing as hypoechoic mostly but occasionally without echogenicity, and lie adjacent to cartilaginous structure (Lento & Primack, 2008).

There has been five studies that have investigated the ultrasonographic findings of symptomatic and asymptomatic joints in the upper limb (Borsa, Jacobson, Scibek, & Dover, 2005; Cheng, Hulse, Fairburn, Clarke, & Wallace, 2008; Elias, Birman, Matsuda, Oliviera, & Jorge, 2006; Jones, England, Muwanga, & Hildreth, 2000; Sasaki et al., 2002). Two studies investigated the GHJ, comparing dynamic USI to stress radiography (Borsa, et al., 2005; Cheng, et al., 2008). One study examined the medial elbow laxity in college baseball players using USI comparing throwing (symptomatic) to non throwing sides (asymptomatic) (Sasaki, et al., 2002). Another study evaluated the role of USI in the diagnosis of acute ulna collateral injuries to the thumb (Jones, et al., 2000). Ultrasonography has also been used to establish normal values of joint space in the Temporomandibular joint (TMJ) (Elias, et al., 2006).

Four studies made specific mention of the field and expertise of the examiners conducting USI in the upper limb (Borsa, et al., 2005; Cheng, et al., 2008; Elias, et al., 2006; Jones, et al., 2000), with one study failing to mention the observer qualifications at all (Sasaki, et al., 2002). The study by Jones et al. (2000) used multiple forms of assessment by different examiners at a large sub regional district hospital including an accident and emergency clinic. Examinations of acute thumb UCL injuries were conducted initially by a senior house officer, where x-rays and initial clinical testing were interpreted and a diagnosis was obtained. At the next available clinic one independent consultant assessed for ligament stability by manual examination, patients were subsequently included into the study if mechanism of injury, clinical signs, radiological indicators and/or presence of joint laxity suggested UCL injury. A single radiology consultant specialising in ultrasonography, blinded to x-ray and clinical diagnosis, was then assigned to assess the UCL with USI. Comparisons in diagnosis were made between the consultant, senior house officers and consultant radiologist

using the Kappa coefficient of agreement (Jones, et al., 2000). Kappa scores of '1' indicate there is complete agreement and scores higher than 0.6 are considered to be a good level of agreement (Jones, et al., 2000). In this study there was strong agreement of 85% and a Kappa score of 0.647 indicating a good level of agreement for assessing the presence of joint laxity between examiners of variable expertise (Jones, et al., 2000).

A study comparing dynamic sonography to stress radiography for assessing asymptomatic GHJ laxity, noted that all USI assessments were done by a radiology technologist, as well as a board certified radiologist with ten years of ultrasonography experience (Borsa, et al., 2005). Each imaging procedure was performed by the same observer using established criteria particular to each method. Intra and inter-observer repeatability were measured using an intraclass correlation coefficient (ICC) formula. All repeatability coefficients were interpreted as 0-0.69 poor, 0.7-0.79 fair, 0.8-0.89 good and 0.90 to 1.00 excellent (Borsa, et al., 2005; Portney & Watkins, 1993). Test-retest repeatability was found to be fair to good with anterior glide 0.72 and posterior glide 0.85. Inter-observer repeatability was found to be excellent for both anterior and posterior glide assessments with 0.96 and 0.99 respectively (Borsa, et al., 2005). In a similar study inferior GHJ laxity was investigated and all assessments were carried out by a senior radiology technician and the first author (Cheng, et al., 2008). Although the qualifications of the first author are not mentioned, reference to experience is described as 'new to the technique' (Cheng, et al., 2008). Measurements for both intra- and inter-observer repeatability was calculated consistent to the previous study by Borsa, et al (2005) using the ICC formula. Intra observer repeatability between the first and second author for inferior GHJ laxity was found to be good to excellent, 0.94 and 0.89 respectively (Cheng, et al., 2008). In addition, inter- observer repeatability was found to be good with an ICC of 0.85. Inter session repeatability for the first author only was found to be excellent with 0.97 (Cheng, et al., 2008).

The last study conducted an USI assessment of 30 TMJ's, investigated by an experienced general radiologist with the support of an oral surgeon (Elias, et al., 2006). Multiple jaw positions were investigated and capsule-condyle distances were measured. Three separate measurements were recorded for each position and intra-observer repeatability was measured once more (Elias, et al., 2006). Lateral capsule-

condyle distance in longitudinal scans was 0.83 for closed mouth position and open mouth position 0.89 (Elias, et al., 2006). Transverse scans exhibited higher ICC values for the open mouth position with 0.91 and similar values for the closed mouth position with 0.83 (Elias, et al., 2006). Anterior capsule condyle length showed excellent repeatability with ICC values of 0.92 for transverse closed mouth and 0.93 for transverse open mouth position scans (Elias, et al., 2006).

A prospective study investigated the accuracy of USI in acute UCL injuries to the thumb MCPJ presenting to a large accident and emergency centre (Jones, et al., 2000). In this study USI was compared to stress radiography, clinical assessment and, in some cases, findings at surgery. In patients with ruptured UCL's of MCPJ treated surgically, USI was found to have a PPV of 94%, a sensitivity of 83% and a specificity of 75%. However in the 12% of injuries that also contained avulsion fractures USI was found to be inaccurate. USI was found to have a higher PPV compared with clinical examination which was 80%. There were three patients that were reported as having an intact UCL on USI examination that were found ruptured surgically (false negatives), although the significant delay before examination may have been a factor in incorrect interpretation due to the formation of scar tissue (Jones, et al., 2000). These results indicating that timing may be a determinant in accurately identifying ligament integrity and subsequent joint stability (Jones, et al., 2000). No other study has examined the sensitivity, specificity or PPV of USI for assessing joint stability as they were primarily investigating normal values and repeatability of the measurements.

A study conducted by Balint & Sturrock (2001) assessed the magnitude of inter and intra-observer errors using USI to measure the distances between the Iliofemoral neck. Two independent examiners with varying expertise blinded to their own and each others results, assessed 22 consecutive normal hip joints. The most inexperienced examiner had undergone no more than a short 3 hour course in hip sonography. Both examiners took ten measurements, which were then placed on a plot diagram and correlation coefficients were used to determine a linear relation between the two observers. The Bland-Altman graphic technique was used to assess the agreement between the examiners. The more experienced examiner had an intra-observer error of 1.11% and the less experienced examiner had an error of 1.47%

suggesting that given the appropriate training an inexperienced musculoskeletal sonographer can achieve satisfactory efficacy (Balint & Sturrock, 2001).

Overall the repeatability of USI for a variety of upper limb joints exhibits good to excellent ICC values indicating high intra-and inter-observer repeatability. These values were consistent regardless of the expertise of the sonographer. Although, the study by Elias, et al. (2006) indicated that when measurements were taken in consensus with an observer with experience of the relevant anatomy - such as a surgeon, higher inter-observer repeatability was observed. However a lower limb study by Balint & Sturrock (2001) found that regardless of experience intra observer errors were low within sessions.

One study compared level of agreement between diagnostic USI and stress radiography to assess inferior GHJ laxity in asymptomatic shoulders (Cheng, et al., 2008). This study used surface anatomy to identify bony landmarks of the shoulder including the superior surface of the coracoid process and the anterosuperior surface of the humerus. The transducer was then placed on the landmark where the most anterior point of the anterosuperior humerus and coracoid process to reveal the joint space. In addition to consistent identification of bony landmarks, this study also employed standardised shoulder positioning and force application using a custom made chair and straps to stabilised the trunk and contralateral shoulder (Cheng, et al., 2008). The earlier study by Borsa, et al. (2005) relied solely on identifying the GHJ via the ultrasound transducer and screen image, describing a hyperechoic flat segment of the posterior scapula and posterior humerus as identification of the joint space. Inter session repeatability of joint translation measurements were relatively lower in this study with 0.72 (fair) and 0.85 (good) for anterior and posterior positions respectively (Borsa, et al., 2005). Comparatively, the inclusion of using surface anatomy may have contributed to the higher ICC of re-test repeatability of 0.89-0.94 for inferior GHJ laxity in the later study (Cheng, et al., 2008). No other study used surface anatomy or soft tissue landmarks, but established known bony landmarks to identify joint space in both thumb MCPJ's and medial elbow joints (Jones, et al., 2000; Sasaki, et al., 2002).

Three studies made specific mention of the measurement tools involved in quantifying joint space on ultrasound images of upper limb joints (Borsa, et al., 2005;

Cheng, et al., 2008; Sasaki, et al., 2002). There was no consistency in regards to the chosen measurement device, with all three studies using a different assessment tool (Borsa, et al., 2005; Cheng, et al., 2008; Sasaki, et al., 2002). A study investigating laxity of the medial elbow in college baseball players used Vernier calipers to measure the width of the medial joint space (Sasaki, et al., 2002). Horizontal and vertical distances were taken from two points, which included the distal medial corner of the Trochlea and the proximal edge of the medial tubercular portion of the coronoid process (Sasaki, et al., 2002). Alternatively, humeral displacement in the study by Borsa et al. (2005) was measured using a digital caliper, which measured the distance between marked hyperechoic points on the scapula and posterior humeral head. Neither study reported the validity of the calipers, which were used, and therefore repeatability of the measurement tools cannot be established and may influence repeatability of results. The later study by Cheng et al. (2008) used a machine based measurement tool, which was not described in detail. Change in distance between the superior surface of the acromion and most anterior portion of the anterosuperior surface of the humeral head was obtained during dynamic examination of the shoulder (Sasaki, et al., 2002). Again validity of the measurement tool was not reported. In addition, the studies comparing USI to stress radiography as the gold standard, used different tools to assess the x-rays and the ultrasound images, which may influence the validity of the comparable values (Borsa, et al., 2005; Cheng, et al., 2008). Further studies investigating validating the use of USI to assess joint translation and laxity need to be established to enable reliable and consistent quantification of distance in both normal and pathological joints.

A number of new techniques developed over the last ten years specifically for musculoskeletal structures have attracted interest as they may provide additional information (McNally, 2011). These include real time sono-elastography (EUS), 3D imaging and image fusion (Klauser & Peetrons, 2010). These techniques have made USI a high ranking imaging modality in the musculoskeletal field as they cater for a wider range of clinical scenarios (Klauser & Peetrons, 2010). Elastography is based upon the principle that the compression of tissue produces strain, where hard tissue produces less strain and soft tissues, higher strain (Klauser & Peetrons, 2010).

However this method is mainly helpful in conjunction with B-mode USI to differentiate between multiple causes of tendon pathology (Klauser & Peetrons, 2010).

3D imaging can provide a complete registration over an entire joint or over several smaller joints (Klauser & Peetrons, 2010). Two dimensional (2D) slices are created and stored in the computer memory, this can be conducted with the operator moving the 2D probe over the volume of tissue or by placing the larger 3D probe over the tissue while the electronic systems of the probe take multiple side by side 2D slices (McNally, 2011). Figure 17 shows the clarity of 3D imaging of vascular tissue.

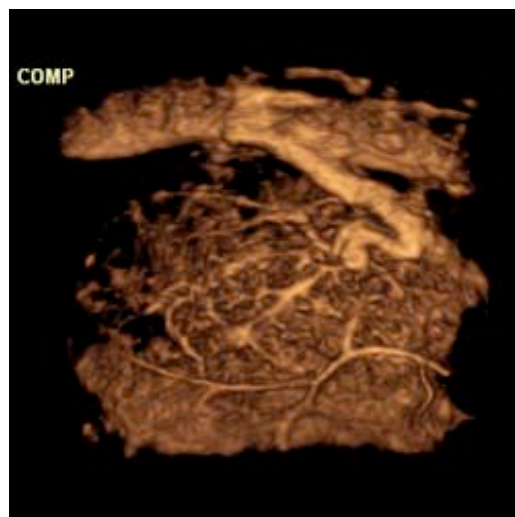


Figure 17: 3D USI of vascular tissue. Adapted from Bonner, J. (2009). Retrieved 12th February, 2012, from <http://www.diagnosticimaging.com/display/article/113619/1386317?CID=rss>

Images can be post-processed in the ultrasound system for computerised objective quantification (Klauser & Peetrons, 2010). 3D imaging is still in its infancy and there have been no studies investigating joint translation, possibly because it is more time consuming and image quality is lower compared to traditional B-mode scans (Klauser & Peetrons, 2010). In addition, post scan analysis loses the real-time advantage of USI and therefore any useful clinical information to be gained from interacting with the patient (McNally, 2011).

Fusion imaging has been described as an exciting development where previously performed CT or MRI data sets are superimposed onto a real time ultrasound image (Klauser & Peetrans, 2010). This technique is shown in Figure 18 and combines the high spatial resolution of cross sectional MRI or CT images and the dynamic aspects of USI (McNally, 2011). The ultrasound image is cross referenced to the imported data using recognisable landmarks superimposing the image acquired via USI (McNally, 2011). Again, the application of this technique in the assessment of joint translation is still to be investigated.

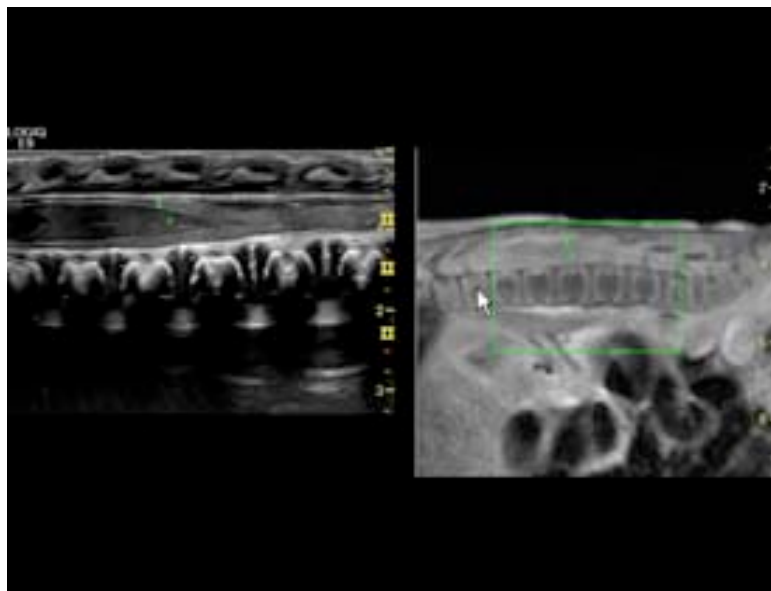


Figure 18: Side-by-side fusion imaging of real-time high-frequency ultrasound and MR images of a neonatal spine. Adapted from Bonner, J. (2009). Retrieved 12th February, 2012, from <http://www.diagnosticimaging.com/display/article/113619/1386317?CID=rss>

In summary, advances are expanding the range of applications that USI offers in the field of musculoskeletal imaging. This has come about due to the advantage of real time imaging, high tissue resolution and relative speed at reasonable costs (Klauser & Peetrons, 2010). In future years, studies with surgical correlation should aim to document the accuracy of USI in a range of musculoskeletal deficiencies. Instabilities affecting the DRUJ can arise from a variety of patho-physiological events and early diagnosis of severe disruption to the stability of this joint is critical to promoting pain free function. There are many inconsistencies reported in the literature regarding the repeatability of several methods for assessing translation at the DRUJ. Overall the diagnosis of DRUJ instability using radiography and MRI remains difficult and CT is often used to evaluate suspected DRUJ subluxation (Burk, et al., 1991). However there are substantial variations in both normal and pathological populations with the current methods of CT scan image analysis. This should be considered when evaluating the DRUJ in symptomatic wrists and clinicians should be careful not to interpret these results in isolation but in conjunction with clinical findings and accurate radiographs. There is limited research surrounding the assessment of joint translation, ligament laxity and subsequent joint stability, particularly in the hand and wrist using USI. In regards to dynamic imaging, USI has significant advantages over other modalities when an extremity is required to be specifically positioned or actively moved to show an abnormality (Jacobson, 2009). Future research should aim to produce consistent results with standardised positioning of the shoulder, elbow and forearm and develop a consistently reliable method of analysis. USI provides a highly accessible, alternative method that is relatively cost effective, quick, pain free and with advancements in technology, produces a high resolution for consistent analysis (Klauser & Peetrons, 2010).

CHAPTER THREE - EXPERIMENTAL AIMS AND HYPOTHESIS

3.1 Research question

This study aims to investigate whether the utilisation of USI to measure DRUJ translation is reliable in a normal population, and if so explore the degree of translation between three different resting positions of forearm rotation and under load. Validity will also be examined by comparing measurements obtained during this study compared to previously documented measurements using CT. It is necessary to firstly establish USI as a valid tool to assess healthy populations before testing a pathological population and making direct comparisons.

3.2 Study Aims

1. To assess the repeatability of measuring DRUJ translation using diagnostic USI
2. To quantify normal values of DRUJ translation in different positions of forearm rotation
3. To validate data collected by comparing to previously documented values established in the literature

CHAPTER FOUR – EXPERIMENTAL DESIGN

4.1 Study Design

A cross-sectional reliability study was carried out in the AUT-Horizon scanning Musculoskeletal Ultrasound Imaging Research Unit. Participants recruited into the study were required to attend a session of testing on two separate occasions comprising of no more than 30 minutes per session. The two sessions were interspaced by no more than four weeks depending on when the participant was available. Images using a Phillips iU22 ultrasound machine were taken by the same observer and stored on an external hard drive for subsequent analysis.

4.2 Ethics

Ethical approval for application number 10/262 was granted from AUTEK (Auckland University of Technology's Ethical Committee) on 23rd December 2010 for a period of three years (Appendix A).

4.3 Participants

A total of 23 healthy participants (46 wrists) that met the study inclusion criteria and consented fully were included in the study. Participants were sourced through advertisements placed throughout the university grounds, as well as sourcing from friends and colleagues. The number of participants sourced for this study was based on availability and not a power calculation as there has been no studies that have used this method to date.

Inclusion criteria allowed healthy adults aged between 18-65 to take part in the study. Participants were excluded if a history of forearm fractures, dislocations or previous wrist pathology were reported. In addition participants with diagnosed rheumatoid arthritis, osteoarthritis or autoimmune conditions were excluded from the study. Baseline demographic data was collected and included hand dominance, age, gender and occupation. Participants were given an information handout (Appendix B) regarding the study that outlined requirements and procedures. The opportunity for any questions was provided and all participants who had given consent and admitted into the study (Appendix C). No adverse events were reported at all throughout the study.

4.4 USI Protocol

4.4.1 Set up

Participants were seated with their feet touching the ground and spine supported by the back of the chair. The forearm was supported using an adjustable plinth positioned next to the chair on the side where measurements were to be taken. The shoulder was positioned in neutral and the elbow positioned at 90°, which was measured with a medium-sized plastic Goniometer. The wrist was positioned over the edge of the plinth in a neutral position that allowed the ultrasound head to access the DRUJ. USI examination was conducted on the DRUJ using a Phillips iU22 diagnostic ultrasound machine with a 55mm linear array transducer (L12-5 Mhz). The ultrasound machine was set to a specific preset labelled 'advanced musculoskeletal superficial' which maintained a preset focus number and depth for this area of the wrist throughout the USI protocol.

4.4.2 Elbow and Forearm positions

The elbow was set in a standardised position of 90° to maintain consistent proximal to distal translation of the ulna (Fu, et al., 2009). The plinth was then adjusted to support the forearm, at the 90° elbow flexion angle measured to maintain this position. Elbow position was measured before each measurement using a plastic goniometer and adhering to the American Society of Hand Therapists (ASHT) guidelines for goniometry (Fess & Moran, 1981).

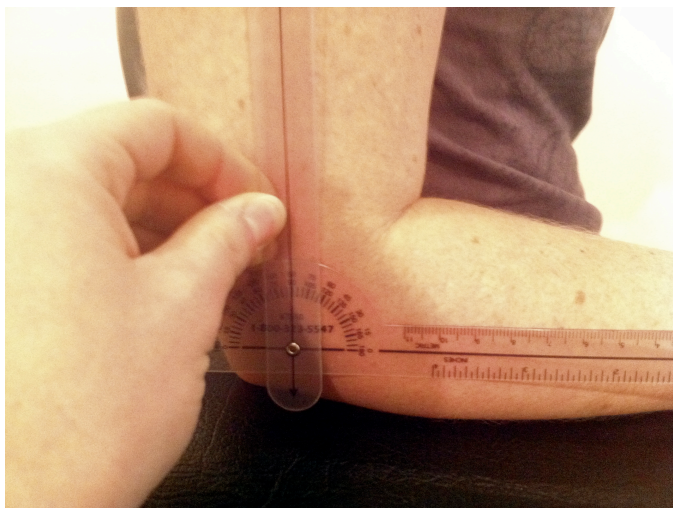


Figure 19: Goniometer measurement of elbow at 90°

The full available range for both supination and pronation was selected along with the neutral position (Figure 20). For the purpose of this study, extreme positions of rotation were chosen as they were likely to exhibit the maximal amount of displacement in healthy participants due to less articular contact between the radius and the ulna (see Figure 21) (Baeyens et al., 2006). In addition, full available pronation and supination are easier to maintain as opposed to specified positions that would have to be measured and controlled.

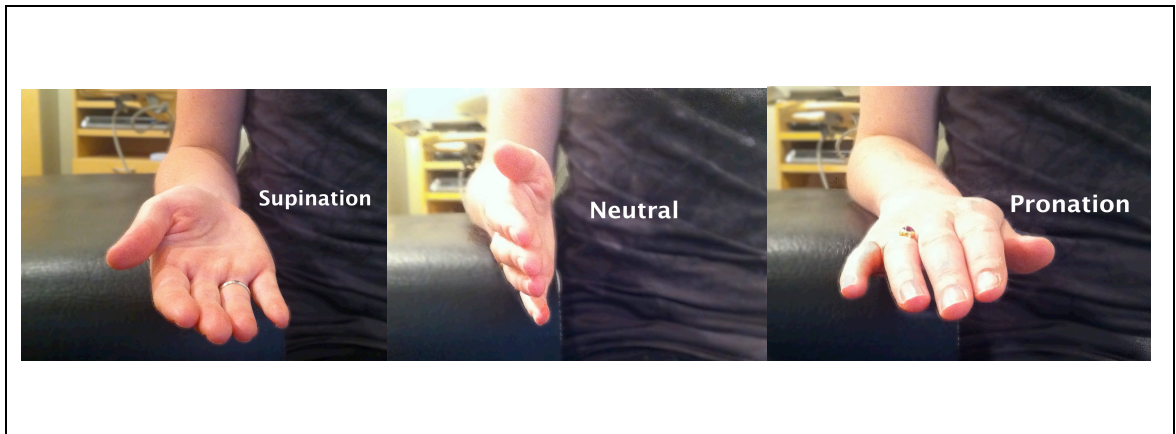


Figure 20: Positions of rotation included for USI analysis

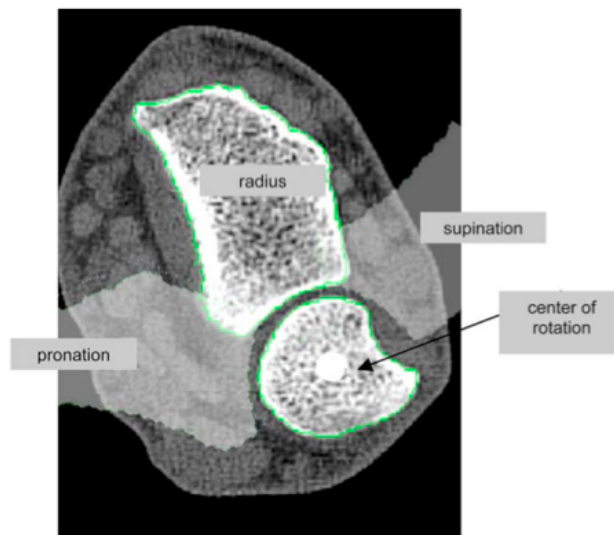


Figure 21: Positions of forearm rotation and articular contact of the DRUJ. Adapted from Baeyens et al (2006). *Clinical Biomechanics*, 21, pp: 12.

4.4.3 DRUJ Location and Identification

The dorsal aspect of the DRUJ was chosen as common bony landmarks are more easily visualized compared with the volar surface. Confirmation of known bony and soft tissue landmarks is important to accurately identify the DRUJ and maintain consistency of the images between participants. The main bony landmarks identified using USI over the dorsal surface were Lister's tubercle on the radius, the ulna head and the ulna styloid (Figure 22). However the ulna styloid was not as easily viewed during maximal pronation due to rotation of the ulna head in this movement. The dorsal lip of the sigmoid notch was easily viewed and was consistent throughout forearm rotation. All six extensor tendon compartments can also be visualised directly dorsal to the DRUJ and are shown in Figures 22 to 26, which were all produced by the author during the current study. Figure 27 depicts all the extensor tendon compartments also.

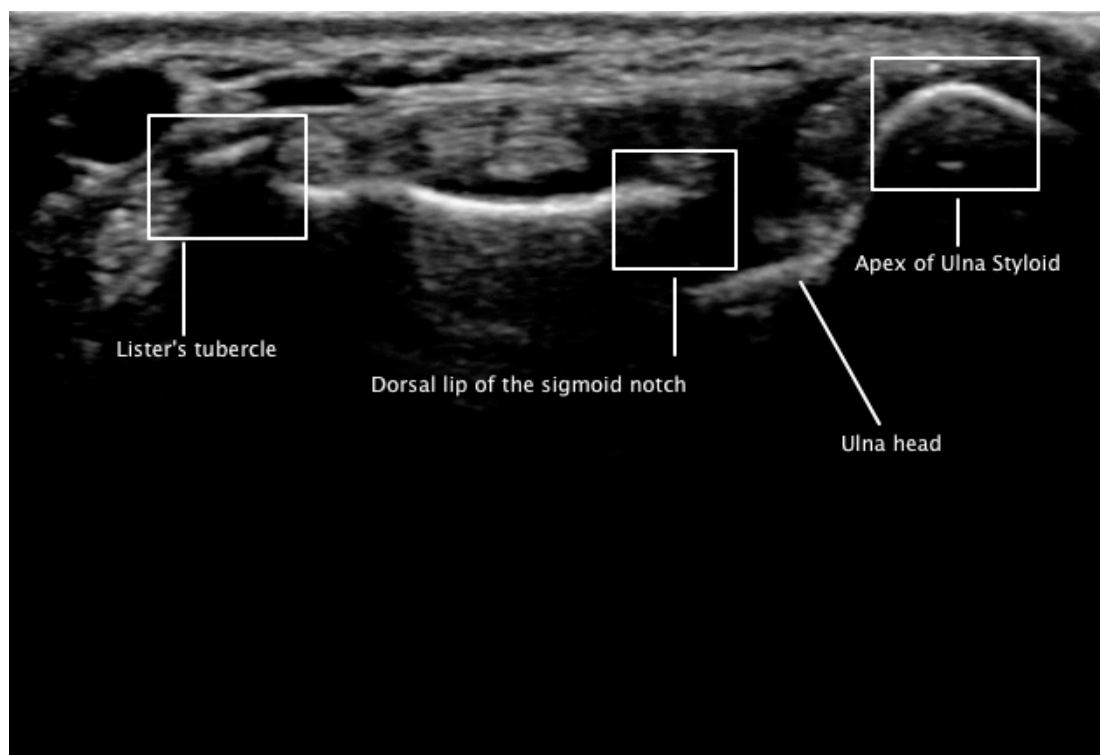


Figure 22: DRUJ bony landmarks seen dorsally in full supination.

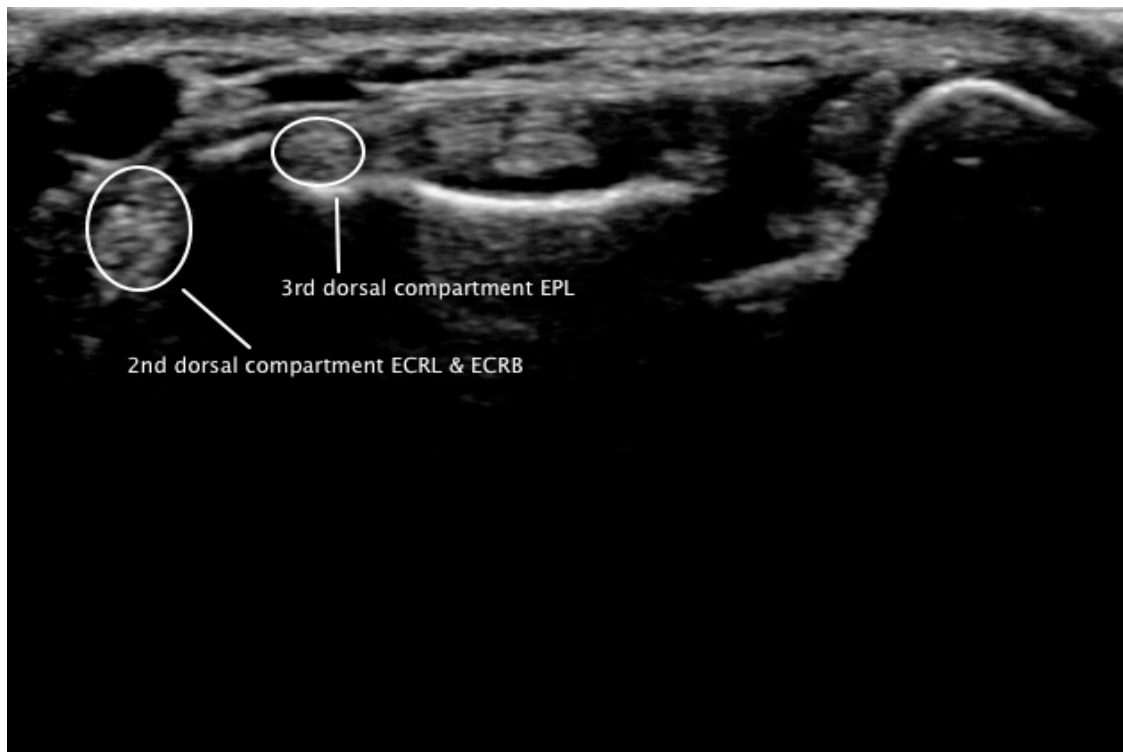


Figure 23: DRUJ soft tissue landmarks: The 2nd dorsal compartment containing extensor carpi radialis longus (ECRL) and extensor carpi radialis brevis (ECRB) which sits radial to the Lister's tubercle, and the 3rd dorsal compartment containing extensor pollicis longus (EPL) sitting in a groove on the ulna to Lister's tubercle in full forearm supination.

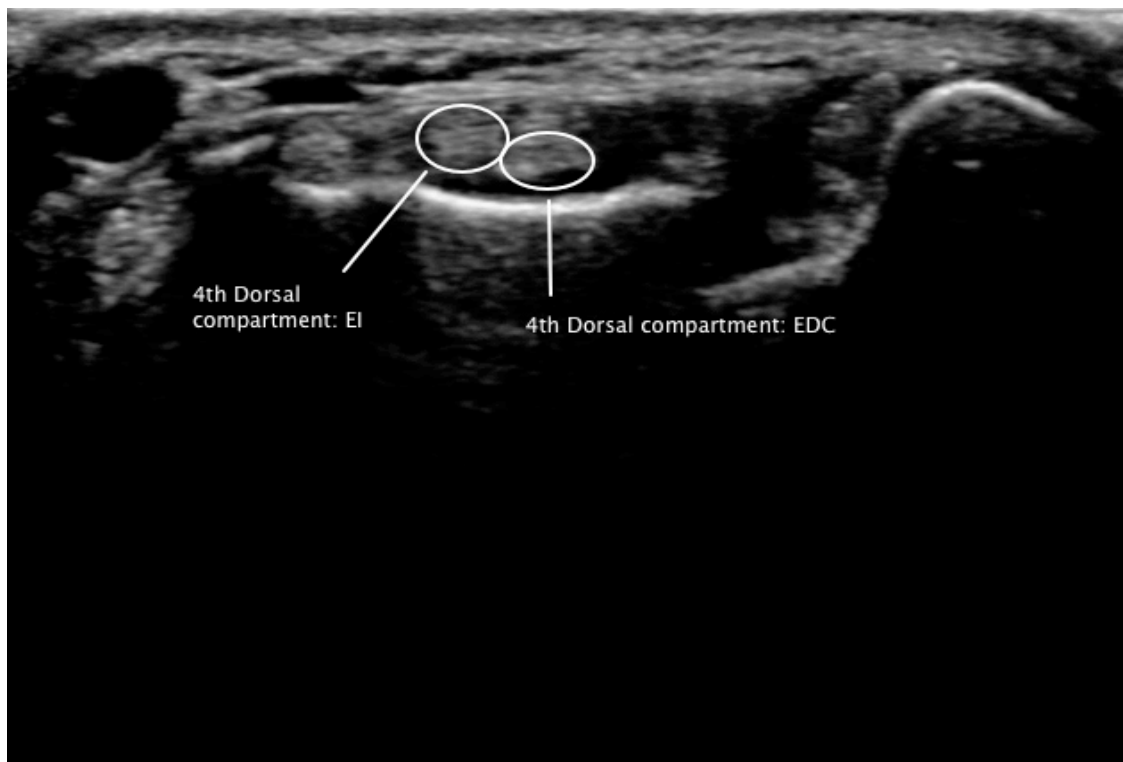


Figure 24: 4th dorsal compartment containing extensor indicis (EI) radially and extensor digitorum communis (EDC), lying dorsal to the radius in full forearm supination.

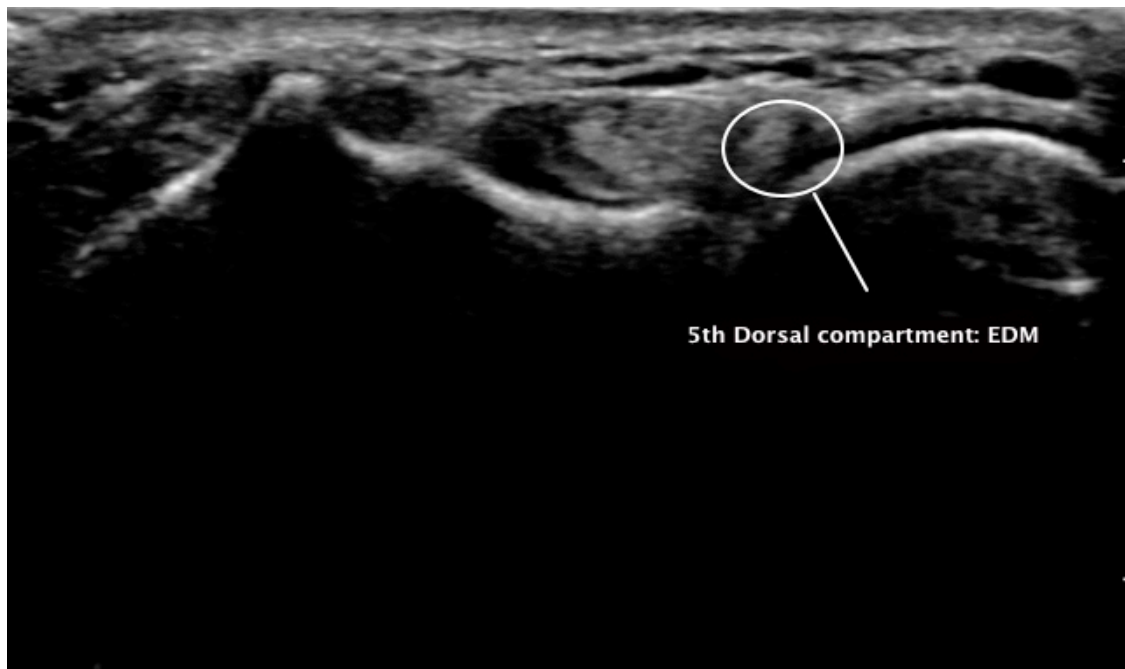


Figure 25: 5th Dorsal compartment containing Extensor Digiti Minimi (EDM) located almost directly posterior to the DRUJ in full forearm pronation

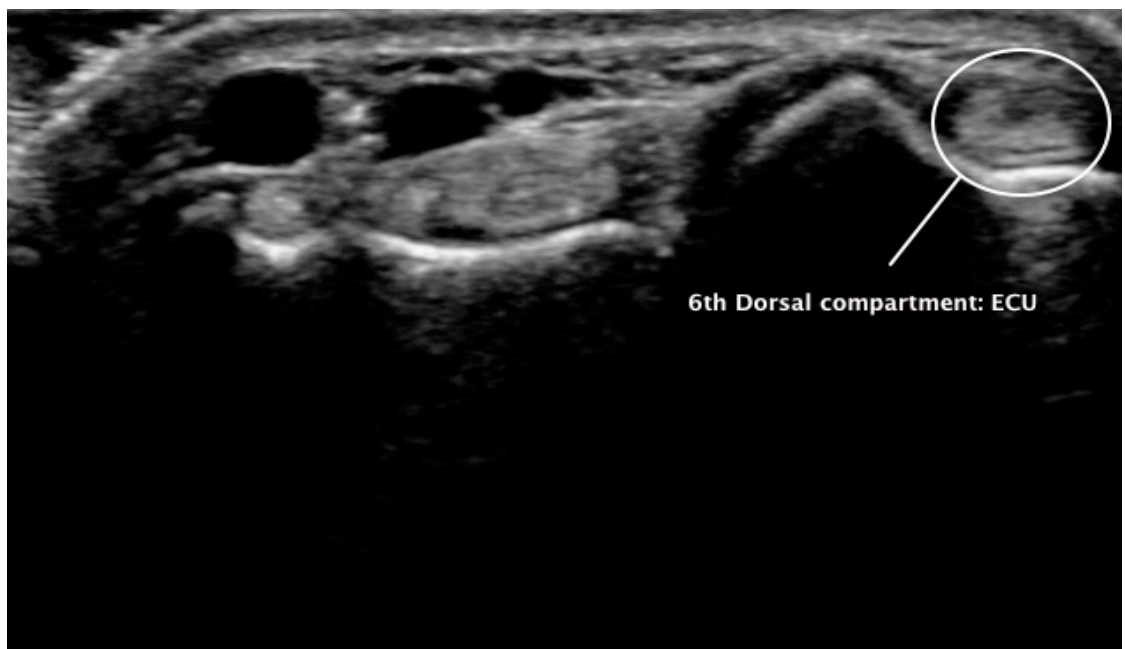

Figure 26: 6th Dorsal compartment containing the ECU located directly posterior to the ulna head in forearm neutral position

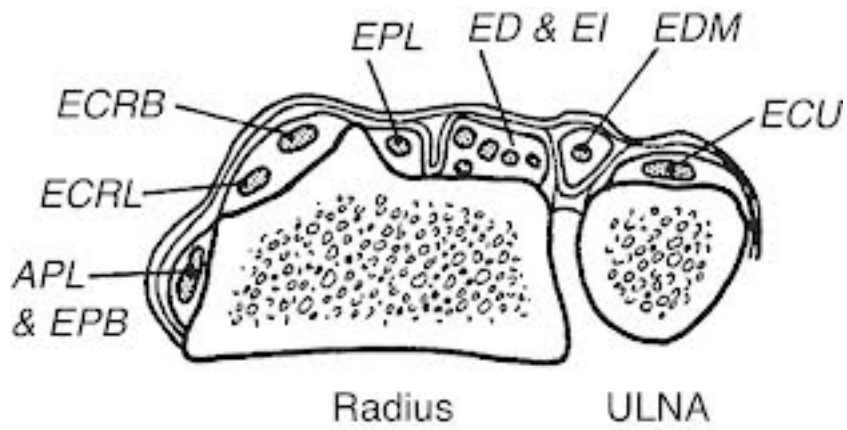


Figure 27: Anatomical compartments and extensor tendons surrounding a sagittal cross section of the DRUJ [Image]. (2010). Retrieved February 1st, 2013 from <http://www.reumatologiaclinica.org/en/clinical-anatomy-of-the-hand/articulo/90178529/>

4.4.5 Scanning procedure

A coupling gel was applied to the linear transducer and was positioned horizontally across the dorsal aspect of the DRUJ, palpated just proximal to the wrist crease in order to capture Lister's tubercle, the sigmoid notch and the entire ulna head as shown in Figure 28. The image was then assessed for quality that included clear pixelation and identification of all bony and soft tissue reference points and landmarks

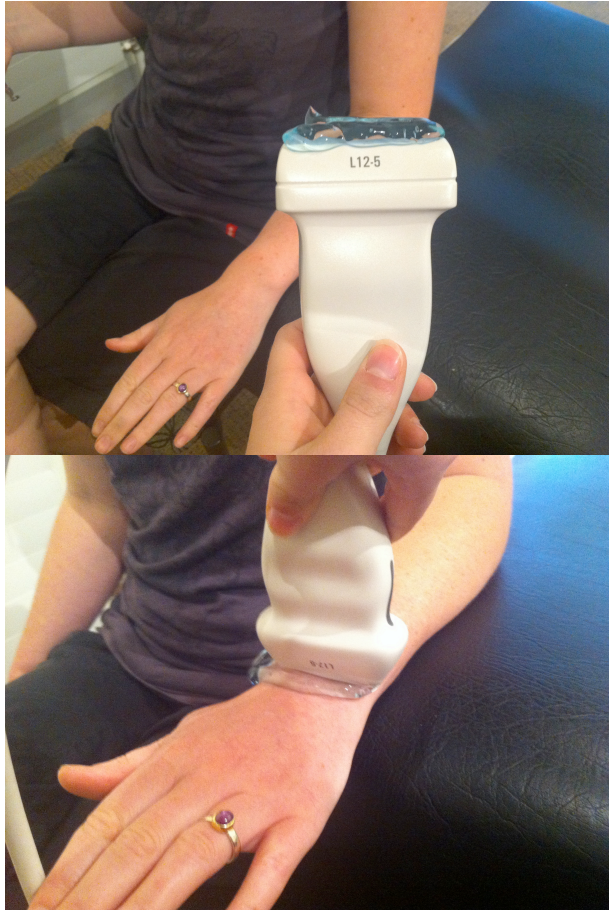

Figure 28: USI set up and DRUJ location

The assessors right hand controlled the transducer perpendicular to the DRUJ and the left hand was free to control the freeze button shown in Figure 29. Once the image was concluded to be acceptable the print button was pressed to save the picture. Each image was annotated on site with the position of rotation (supination, neutral or pronation), state (non gripping or gripping) and number of the measurement (1, 2 or 3).

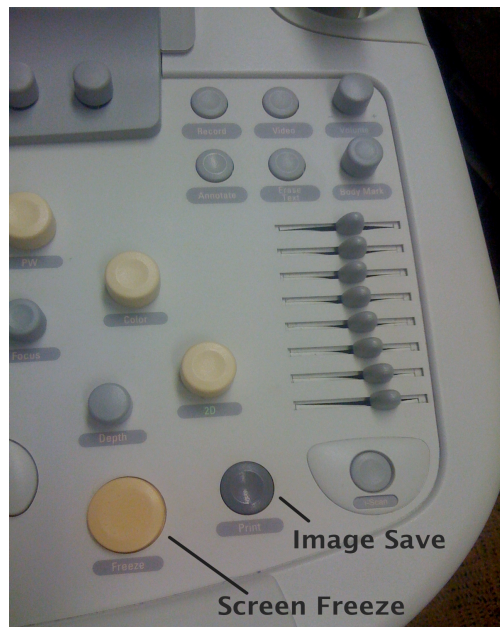

Figure 29: Ultrasound buttons used during image capture

Images of maximal supination, neutral and maximal pronation was taken three times for each position. This process was repeated with the participant gripping a 1kg weight. Participants were given standardised instructions to grip onto the weight with maximal force until the image was taken. There was a rest period of one minute between each grip test to allow for adequate muscle recovery and avoid fatigue of surrounding soft tissue structures. Once again three separate readings of only maximal supination and pronation were recorded for each image. It was chosen to exclude the neutral position from the gripping measurements as this position is considered to inherently be the most stable in regards to joint congruency. All images were reviewed for satisfactory visualisation of the joint space including bony and soft tissue landmarks. These were revised with extra scans and deleted if considered unacceptable if the bony landmarks were blurry, could not be easily visualised or were missing from the image.

Participants attended on two separate occasions and the scanning procedure was conducted without variation twice with no more than a four week stand down period. Only one participant failed to attend the follow up session and their results were omitted from the analysis. Participants were not blinded to the scanning procedure but were blinded to the measurement process.

4.5 Image Analysis

There were 15 images taken of each wrist during each session. All images were saved, stored on a MacBook and backed up on an external hard drive. Overall 1380 images were inserted as Jpeg's into the Sketchbook Express software program. Sketchbook express allowed quick and efficient parallel and perpendicular lines to be drawn. Using Sketchbook Express, two parallel lines were drawn; one through Lister's tubercle (A) and the dorsal lip of the sigmoid notch and the other through the apex of the ulna head (C). A perpendicular line 90 degrees to these lines through the apex of the ulna head was then drawn and the points of intersection on the parallel lines were identified (B). This method, which is shown in figure 30, is consistent with the RASR method described by Henmi et al, (2007). This method allows for variations in bony anatomy and has been found to be highly sensitive in detecting subluxation of the DRUJ (Henmi, et al., 2007). These new images were then transposed and loaded into the ImageJ software program where the intersecting points (BC) were measured giving the final measurement of displacement in mm. The figures below show each step of image analysis. ImageJ can calculate area and pixel value based on user known selections and subsequently measures distances. However, ImageJ was limited in its ability to draw exact parallel and perpendicular lines in as little time as the sketchbook express programme.

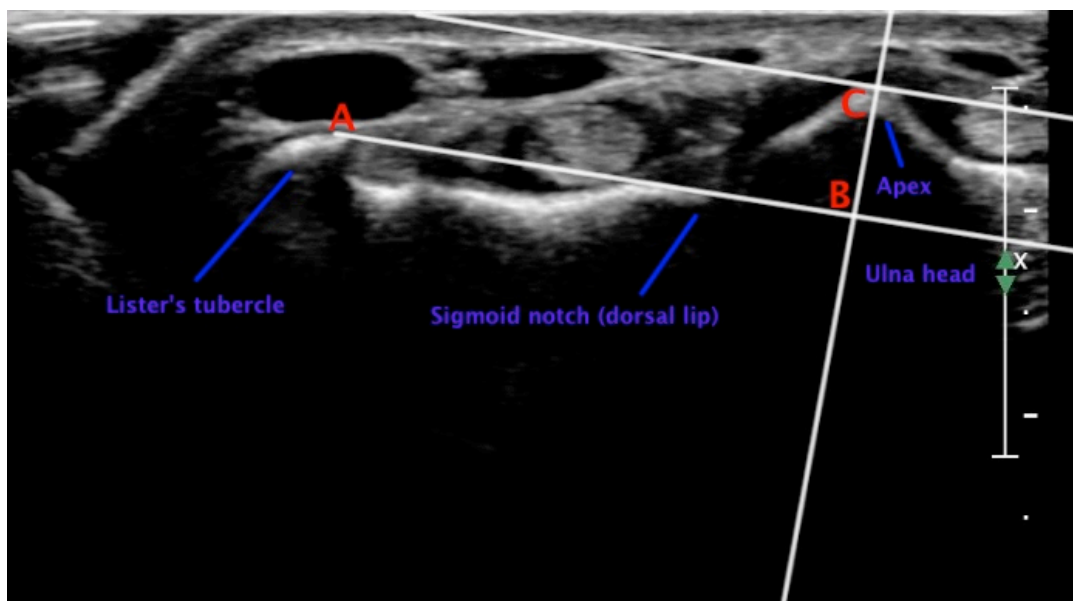


Figure 30: Analysis of ultrasound image: Lines drawn relative to established bony landmarks indicating DRUJ displacement modified from the RASR method explained by Henmi et al, (2007). Translation was measured in mm between points of B and C. Ratio values to assess validity consistent with the RASR method used distance in mm of BC/AB

Statistical analyses of baseline descriptive data on each participant using the Statistical Package for the Social Sciences (SPSS) version 17 software (Chicago, IL) and Microsoft Excel.

A hierarchical mixed model was constructed to analyse differences between both forearm position and state (gripping versus non gripping), as this was thought to be the most suitable representation of the data. The model incorporated two random effects in a hierarchical organisation: a random intercept per person and another random intercept per person's hand. These allow for variation caused by randomly sampling people and by the fact that a person's hand size may vary. Residuals or unexplained variables in the model were also analysed. The residuals are the variation left unexplained in the model, which could be interpreted as the error inherent in the repeated measurement process. This model is suited to generalising the data and estimating real differences between forearm position and state in a wider population, rather than assessing the accuracy of the measurement tool.

ANOVA was used to compare each position of forearm rotation and also the non gripping and gripping test measurements

Within session repeatability was analysed using Cronbach's alpha, which is described as a measure of internal consistency, particularly when assessing multivariate measurements comprised of correlated items. Acceptable values range between 0.7 and 0.8, and values substantially lower than this indicate an unreliable scale (Field, 2005)

Paired sample t-tests and the ICC measure were used to determine whether there was a significant difference between the average value of the translation between session one and two (Easton & McColl, 2012). In this study the paired t tests investigated 10 paired samples; three non gripping positions (supination, neutral and pronation) and two gripping positions (supination and pronation), which were repeated for both left and right hands (e.g. $2 \times 5 = 10$). ICC's were used to compare the mean in mm of session one to the mean of session two.

CHAPTER FIVE – RESULTS

5.1 Demographics

Of the 24 participants included in the study, the average age was 41 (Age range of 18-53) and all the participants were right hand dominant apart from two (8.3%). Fourteen of the participants were female (58%) and ten were male (42%). All participants attended the first session however one participant was unable to attend the follow up session due to time commitments so their results were not included in the final analysis. The standard deviations of the random components in the model were analysed and all three closely demonstrated normal distribution, with mean zero. Variation between participants was 1.1mm and within participants, i.e. hand variation was 0.48mm. The residuals of the model had a standard deviation of 0.82mm.

5.2 Forearm positions and states

Translation was found to occur in both non gripping supination and pronation compared with neutral ($p < 0.001$). There was significantly more translation found with pronation where ulna radial translation occurred in a dorsal direction compared with the neutral position (mean=1.69mm). Ulna radial translation in supination was also found to be highly significant but there was less translation in a volar direction compared with neutral (mean=0.67mm).

Gripping measurements of translation were compared to the corresponding non gripping positions to determine if there was a difference between the two states. Gripping pronation did not produce statistically significant changes in ulna radial translation compared to non gripping pronation. However, ulna radial translation with gripping supination was significantly higher ($p < 0.01$) in comparison to the non gripping position. Table 4 summarises the data and figures 31 to 34 provide a graphical description of the data and results.

Table 4: Mean translation values and significance

State	Position	N	Translation (mm)		Median	Mean	3rd Qu.	Max.	Differences means of		p-value
			Min.	1st Qu.					cf Neutral	cf Resting	
Non gripping	Supinated	276	0.84	2.84	3.99	3.99	5.03	7.67	-0.67		***
Non gripping	Neutral	276	1.91	3.38	4.57	4.66	5.41	8.49			
Gripping	Pronated	276	2.99	5.25	6.41	6.35	7.48	9.89	1.69		***
Gripping	Supinated	276	0.94	3.16	4.08	4.21	5.24	7.99		0.21	**
Gripping	Pronated	276	3.37	5.38	6.27	6.42	7.46	9.85		0.06	NS

Note p-values: *** < 0.001; ** < 0.01; * < 0.05; NS (non significant) >= 0.05

N= number of images

Qu. = Quartile

The mixed model adjusted for nested random effects for participants and hands.




Figure 31: Box plot diagrams showing displacement values (translation) for three non gripping positions showing significant variation between positions for all participants

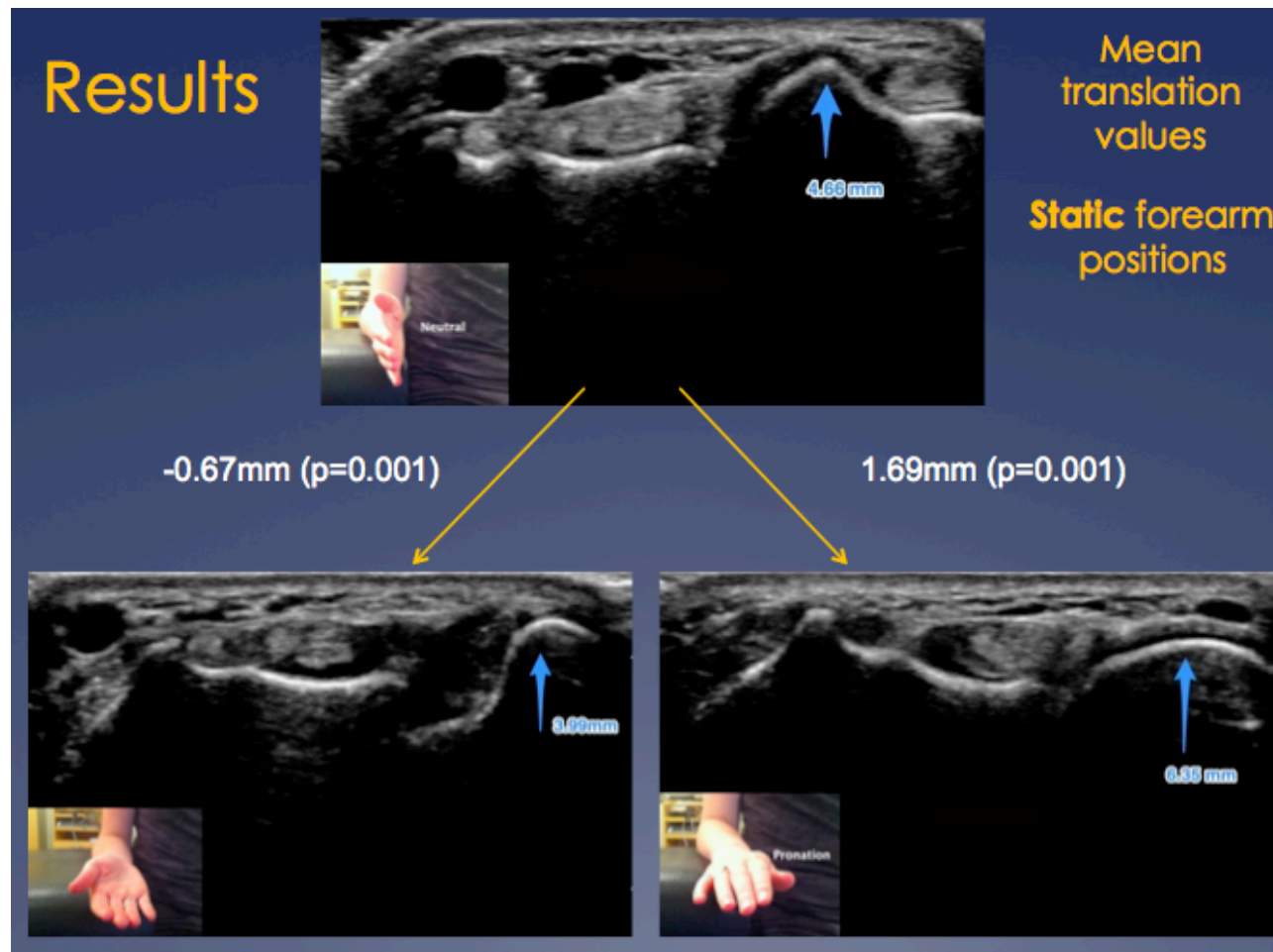


Figure 32: Non gripping (Static) forearm positions: Mean values of difference in translation between neutral position (above centre) and supination (bottom left) and pronation (bottom right)

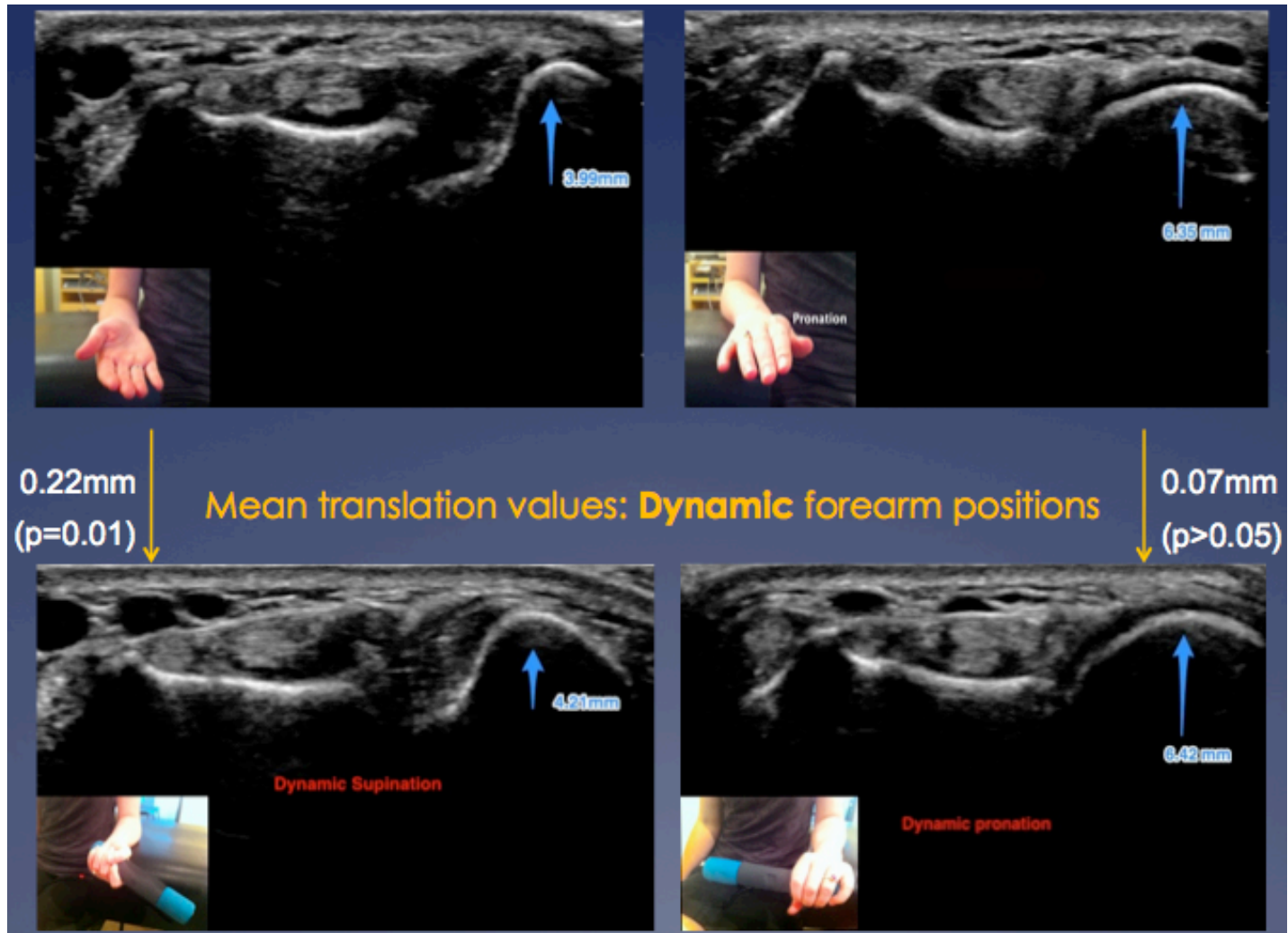


Figure 33: Gripping (dynamic) forearm positions: Mean translation values between non gripping and gripping supination (left), and non gripping and gripping pronation (right)

5.4 Repeatability

5.4.1 Within session

Cronbach's alpha measurement for internal consistency was excellent across all participants demonstrating a correlation coefficient of 0.9 and above for the three measurements. Cronbach's alpha repeatability coefficient normally ranges between 0 and 1 (George & Mallery, 2003). However, there is actually no lower limit to the coefficient (George & Mallery, 2003). The closer Cronbach's alpha coefficient is to 1.0 the greater the internal consistency of the items in the scale (George & Mallery, 2003). George and Mallery (2003) provide the following interpretation s for Cronbach's alpha correlations “ $\alpha > .9$ – Excellent, $\alpha > .8$ – Good, $\alpha > .7$ – Acceptable, $\alpha > .6$ – Questionable, $\alpha > .5$ – Poor, and $\alpha < .5$ – Unacceptable”. The results are presented in Table 5 below.

Table 5: Within session repeatability analyses

Forearm position & state	Cronbach's alpha of session 1	Cronbach's alpha of session 2	Interpretation of consistency (George & Mallery, 2003)
Left wrist			
Non gripping supination	.985	.984	Excellent
Non gripping neutral	.970	.977	Excellent
Non gripping pronation	.960	.964	Excellent
Gripping supination	.942	.969	Excellent
Gripping pronation	.922	.929	Excellent
Right wrist			
Non gripping supination	.955	.975	Excellent
Non gripping neutral	.975	.980	Excellent
Non gripping pronation	.961	.943	Excellent
Gripping supination	.951	.982	Excellent
Gripping pronation	.948	.946	Excellent

5.4.2 Inter-session

Repeatability between two separate sessions of testing is presented below in Table 6. Interpretation of the ICC in categories described by Vincent (2005) is also presented. Although there was no significant difference in translation between left and right hands, the SPSS programme separated the two variables during analysis.

Table 6: Inter-session repeatability analyses

Forearm position and State	Within session mean (mm) of session 1 (95% CI)	Within session mean (mm) of session 2 (95% CI)	ICC	Interpretation of Repeatability (Vincent, 2005)
Left hand				
Non gripping supination	4.01 (2.44 -5.58)	3.88 (2.66-5.01)	.794	Moderate
Non gripping neutral	4.78 (3.24 – 6.32)	4.75 (3.38 – 6.1)	.857	Good
Non gripping pronation	6.51 (5.03 - 7.99)	6.45 (4.84 – 8.04)	.865	Good
Gripping supination	4.15 (2.76 – 5.53)	4.393 (3.00 – 5.78)	.890	Good
Gripping pronation	6.32 (5.006 – 7.64)	6.196 (5.01 – 7.39)	.876	Good
Right hand				
Non gripping supination	3.97 (2.35- 5.59)	4.15 (2.46-5.84)	.93	Excellent
Non gripping neutral	4.73 (3.304 – 6.15)	4.62 (3.05 – 6.20)	.88	Good
Non gripping pronation	6.41 (5.17 – 7.66)	6.39 (5.07 – 7.7)	.80	Good
Gripping supination	4.31 (2.57 - 6.05)	4.01 (2.535 – 5.49)	.90	Good
Gripping pronation	6.49 (4.94 – 8.05)	6.69 (5.17 – 8.20)	.62	Low

Figure 34 demonstrates that the differences are due to the position of supination (P1) and pronation (P3). This is only for the first measure of each set of data but the average for supination is less than the average for pronation regardless of all the other variables. There is only a very minor difference with non gripping versus gripping states. Paired t tests of position, state and side being scanned were found to have no significant difference between sessions, however two measures were close to $p < 0.05$. The paired samples correlation was excellent for one measurement (0.93), good for seven measurements (0.8-0.90), fair for one measurement (0.79) and poor for only one measurement set (0.62).

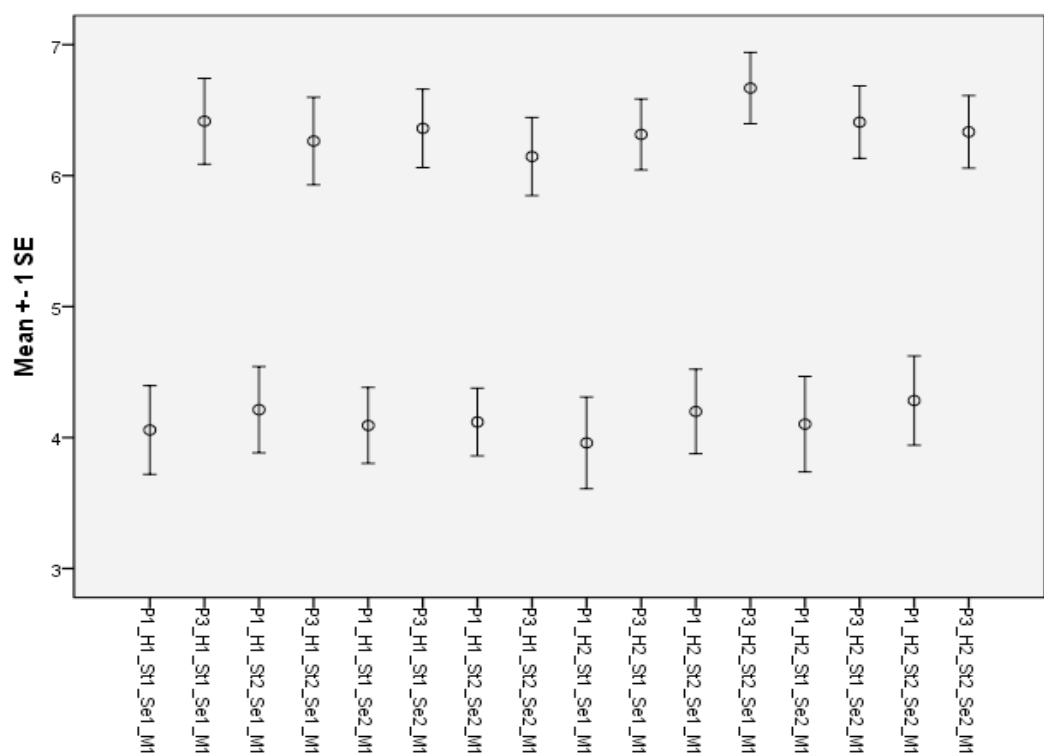


Figure 34: Error bar graph showing measure one (M1) of supination (P1) and pronation (P3) for non gripping (St1) and gripping (St2) for both hands (H1 & H2) sessions (S1 & S2).

5.5 Validity

Validity was assessed by calculating the RASR method previously described in Chapter Two by Henmi et al. (2007). The study by Henmi et al. (2007) examined the RASR in only maximal pronation in ten healthy wrists. In our study the full pronation position of 46 normal wrists during session one was examined using the RASR. All values were placed into an excel spreadsheet and mean and standard deviation (SD) were calculated

The RASR values in the current study demonstrated a mean of 0.239 and a standard deviation of 0.44. These values are consistent with the previous CT study by Henmi et al. (2007), which reported a mean of 0.106 and a SD of 0.072.

CHAPTER SIX – DISCUSSION AND CLINICAL IMPLICATIONS

This discussion pertains to the results of the current study that investigated USI as a new method for quantifying normal values of DRUJ translation. Firstly, a rationale of the chosen methodology and bony landmarks will be presented. Secondly, the normal translation values found in this study will be discussed, followed by the repeatability of these findings and validity of the study. Limitations of the study design will also be presented. Lastly clinical, socio-economic and research implications will be presented and further recommendations for future research will be considered.

6.1 Study design

6.1.1 Probe selection.

The selection of the ultrasound probe is critical to the repeatability and quality of images obtained (Luck, 2008). A linear array transducer was selected as they have been shown to reduce anisotropic artefact compared with curvilinear probes (Luck, 2008). Anisotropy is a phenomenon where the appearance of the structure varies depending on which angle it is being examined at (Luck, 2008). When the inonating sound beam is not perpendicular to the structure of interest, the sound reflects off the structure and away from the transducer resulting in a hyperechoic “drop off” (Luck, 2008). However this effect is less common when assessing cortical structures as opposed to acoustically reflective structures such as ligaments, tendons, muscles and nerves (Luck, 2008).

Additional technical factors that affect the quality and subsequent repeatability of ultrasound images is the dependence on transducer placement (Lento & Primack, 2008). The beam angle should be at a 90 degree angle to the structure being imaged (Lento & Primack, 2008). Deviation of this angle may cause reflection of the beam away from the transducer causing a reduction in echogenecity of the structure being examined increasing anisotropy (Lento & Primack, 2008). There are few suggestions on how to minimise anisotropy, Lento & Primack (2008) advise that good technique can be maintained by ensuring the beam is perpendicular to the tissue involved, maintaining adequate skin contact and choosing the appropriate transducer size for the situation. Wang et al. (1999), suggest that to prevent loss of probe contact on

curvilinear joint surfaces, in the absence of a gel stand off pad, a thick layer of gel and minimal probe pressure can ensure adequate visualisation. The consistency of images can also be highly dependent on body condition and composition, with the ultrasound wave penetrance into tissue, inversely proportional to the wave frequency (Lento & Primack, 2008). For example in some cases scanning of an obese or extremely muscular person can be extremely limited as the linear array transducers can generally only visualise very superficial structures with high resolution (Lento & Primack, 2008). The wrist is generally not covered by a lot of muscle or adipose tissue, making the surface of the DRUJ easily visible in addition to recent advances to high frequency linear ray transducers (Lento & Primack, 2008).

6.1.2 Participant positioning

It was chosen to position all participants seated with their spine supported in chair. The same chair was used throughout the study. This position was chosen as with the support of the adjustable plinth to the side, the elbow could be positioned in 90° without the use of a fixed custom designed device. The wrist was neutral but unsupported to allow the probe to access the dorsal aspect of the DRUJ in supination. This may have been a source of variation as slight changes from neutral could not be controlled for. Early in piloting a customised device to control for wrist and forearm position was considered, but this would have restricted access to the DRUJ and was very expensive to fabricate. However, slight flexion and extension at the wrist is considered to take place purely at the radiocarpal joint and the midcarpal joint, with minimal influence from the DRUJ so that variation on measurements would be non significant (Stuart, et al., 2000). The study by Stuart et al. (2000) found that wrist motion had no significant effect on DRUJ stability. Furthermore, the dynamic effects of the ECU subsheath, PQ and ulnocarpal ligaments throughout wrist motion had no significant effect on DRUJ stability, provided both the PRUL and DRUL were intact (Stuart, et al., 2000). However there is mixed consensus regarding the contribution of the ECU subsheath and PQ to the dynamic aspects of DRUJ kinematics. Further research should be done to determine the effect of wrist position and the dynamic contribution of the ECU subsheath and PQ on DRUJ kinematics.

It was chosen not to abduct the shoulder as described by Mino et al. (1983), as early in piloting this was uncomfortable in the shoulder for the participants. Also this

position made it difficult to access the DRUJ in full supination. This position is mainly used to assess for true ulna variance, and proximal to distal translation (Mino, et al., 1983). Our study only assessed translation in the sagittal plane, and shoulder neutral was chosen as this was a comfortable and easily controlled position. It is unknown whether shoulder position influences the DRUJ in a sagittal plane. Another way to control neutral shoulder position would be to use a belt around the participant's upper arms and torso, however participants maintained a satisfactory position throughout the scans and this was deemed unnecessary.

6.1.3 Line drawing analyses

The RASR method described by Henmi et al. (2007), was used to assess translation for several reasons. The first is that this was the only method that utilises landmarks on the dorsal aspect of the DRUJ. Furthermore, it takes into account and adjusts for, variations in bony anatomy as it is designed to measure participants with rheumatoid disease. As mentioned in further detail below, in our normal study population, there was extensive variation of the bony surfaces and landmarks. Another reason is that this method was found to have superior repeatability compared to other methods mentioned in the literature (Henmi, et al., 2007). During this study the method was adapted slightly to quantify distance in mm, however to assess validity of USI the ratio was calculated exactly as described by Henmi et al, (2007), for non gripping pronation position.

6.2 Bony Landmarks and anatomical variations

The dorsal aspect of the DRUJ was chosen for scanning despite the volar aspect offering a more planate and level surface to place the ultrasound probe. The lack of consistent bony landmarks on the volar surface decreased reliable identification of the joint space and made analysis difficult during early piloting. Dorsally, Lister's tubercle on the radius and the large ulna head and styloid were demonstrated consistently throughout the images. However, substantial variations in the anatomical shape and size of these landmarks were seen across the participant population and may have caused variation in some results. Tables 7, 8 and 9 show the variations seen in all three positions. Forearm pronation exhibited the least variation of the ulna due to the ulna styloid not being visible. Across all positions Lister's tubercle also demonstrated considerable variation across numerous participants.

Figure 35: Anatomic anomalies seen in supination using USI of the DRUJ

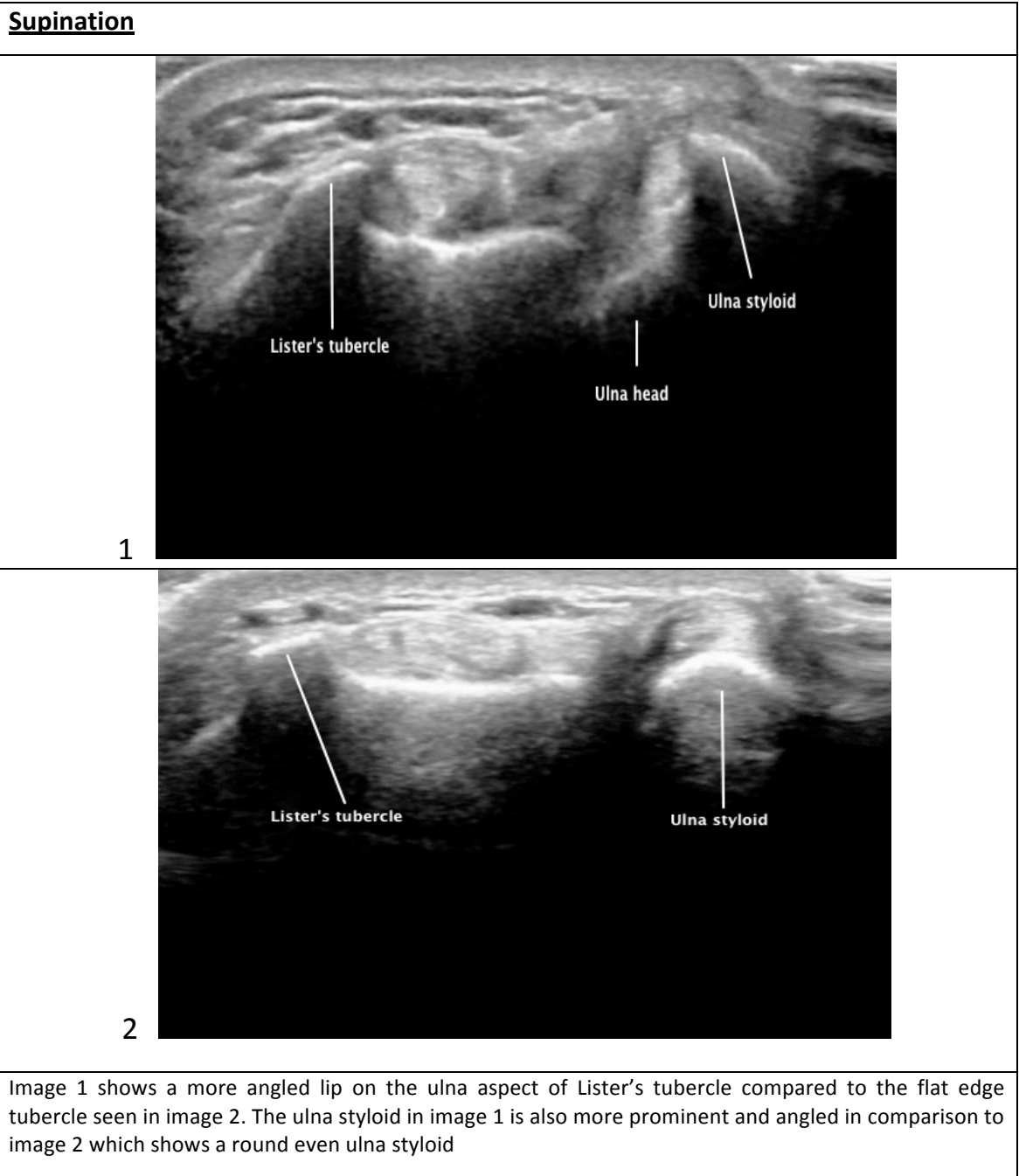


Figure 35: Anatomic anomalies seen in supination using USI of the DRUJ

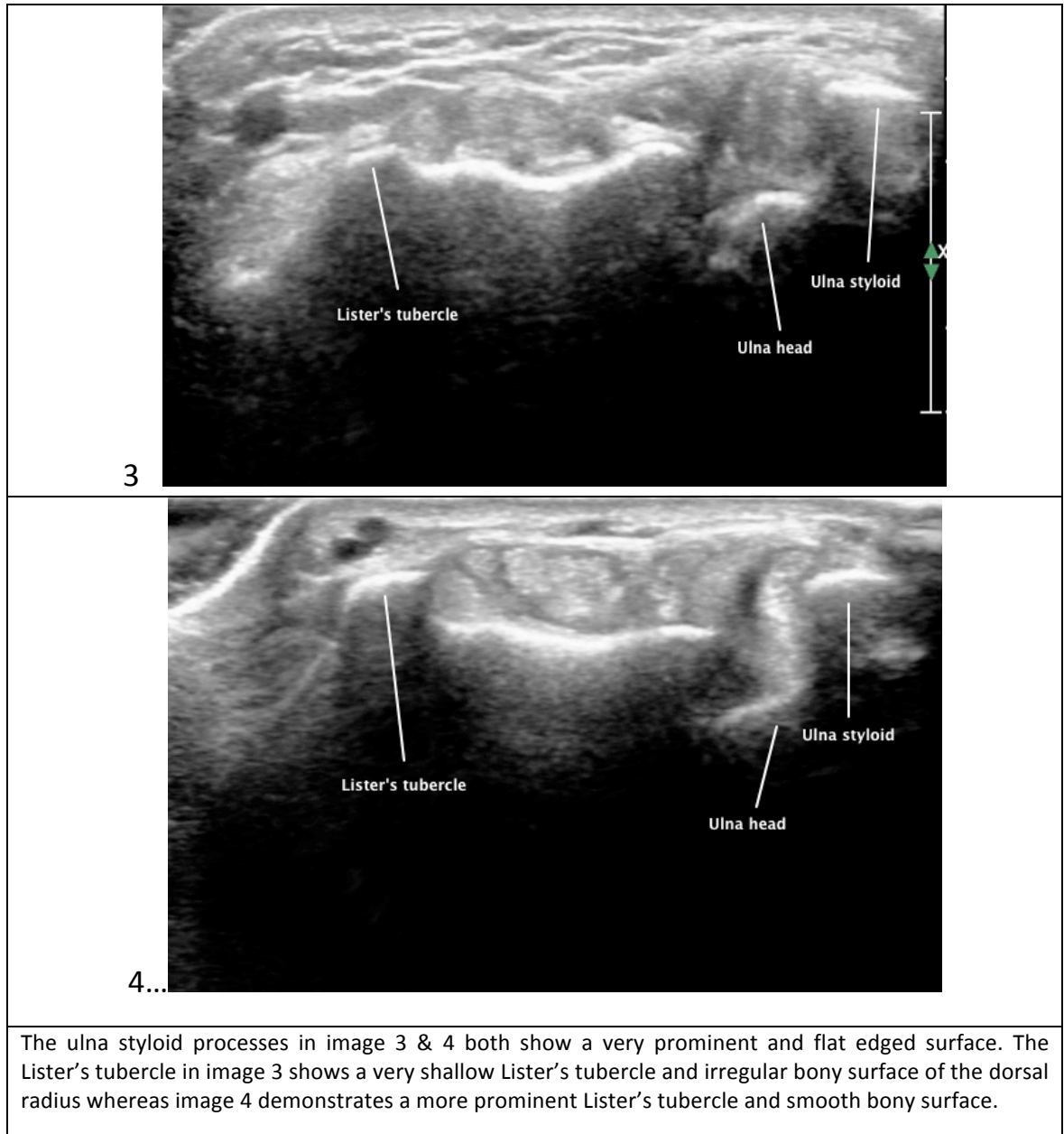
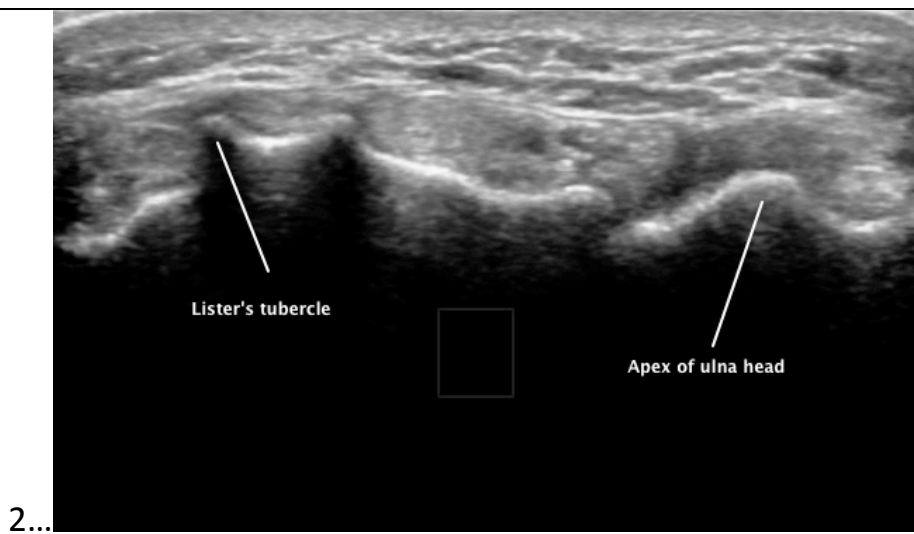
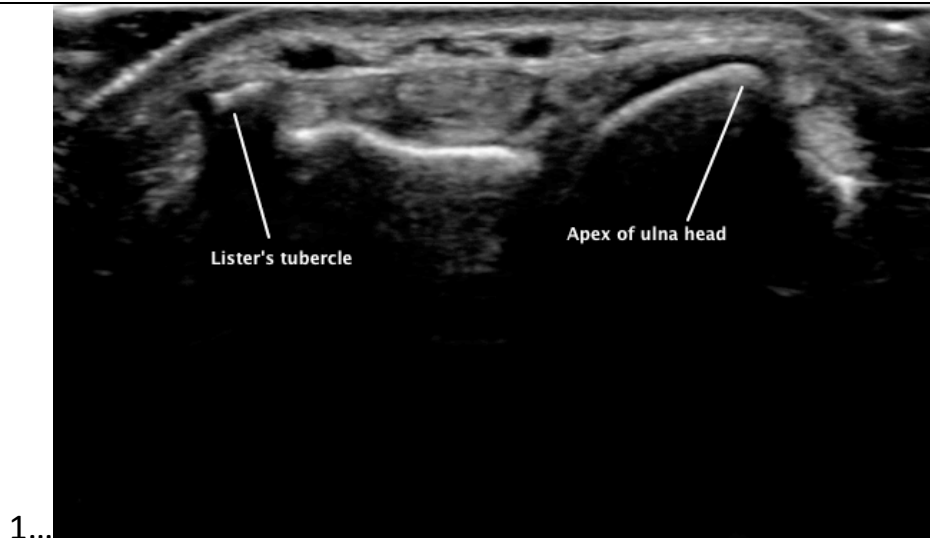


Figure 36: Anatomic anomalies seen in neutral using USI of the DRUJ

Neutral



The shape of the ulna head demonstrated significant variation in the neutral position. Image 1 depicts a prominent angled Ulna head, whereas image 2 exhibits less prominence and a more rounded edge to the ulna head.

Figure 36: Anatomic anomalies seen in neutral using USI of the DRUJ

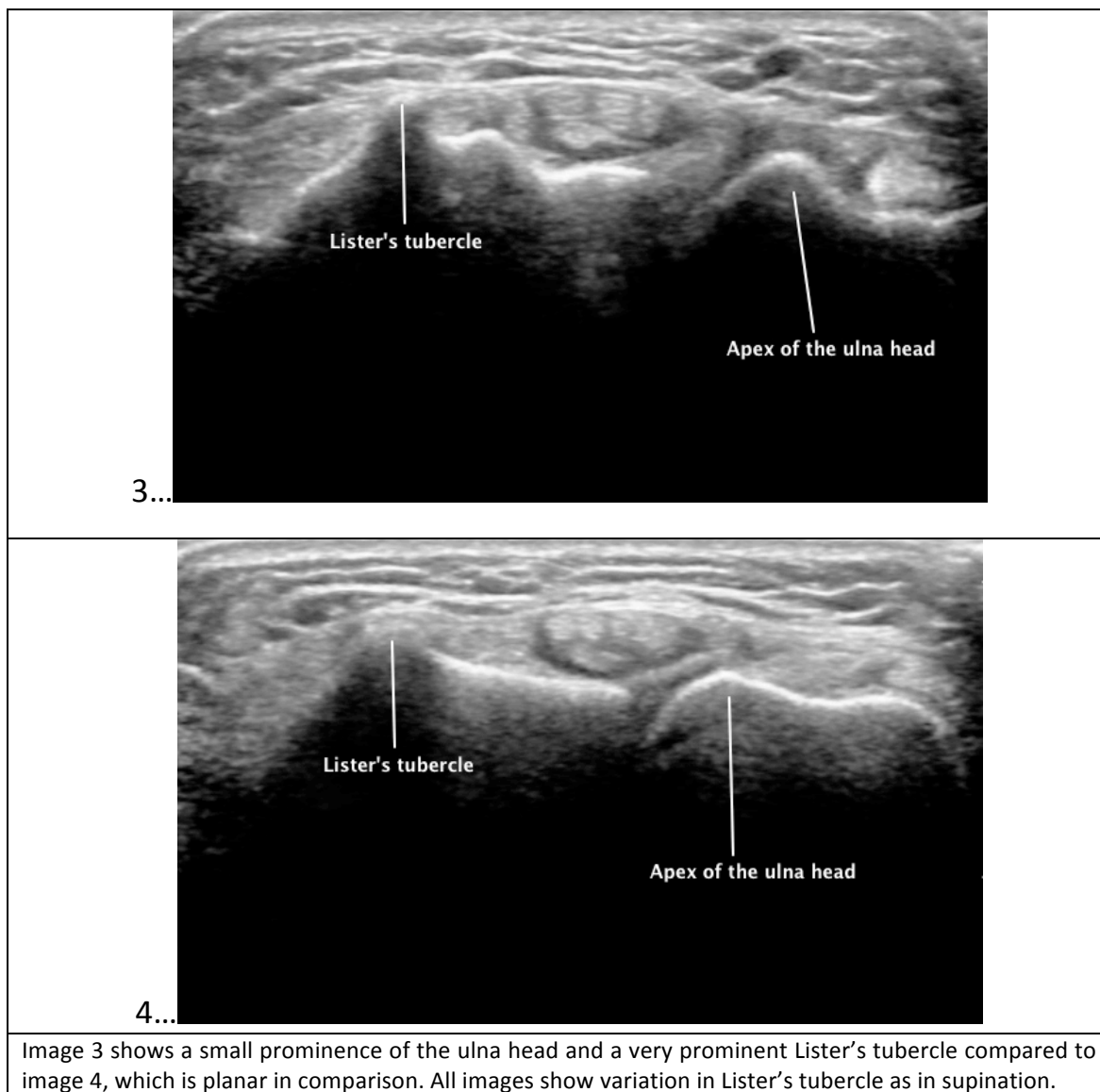
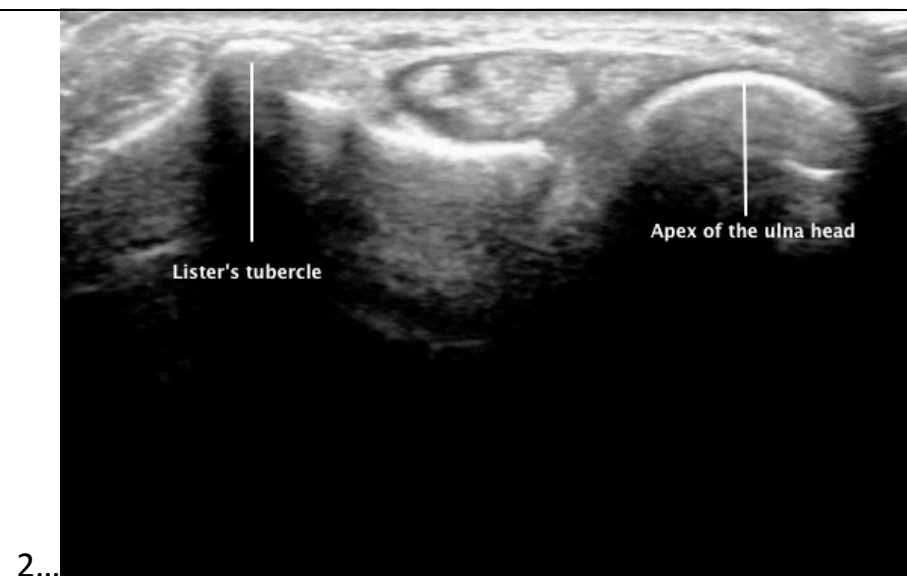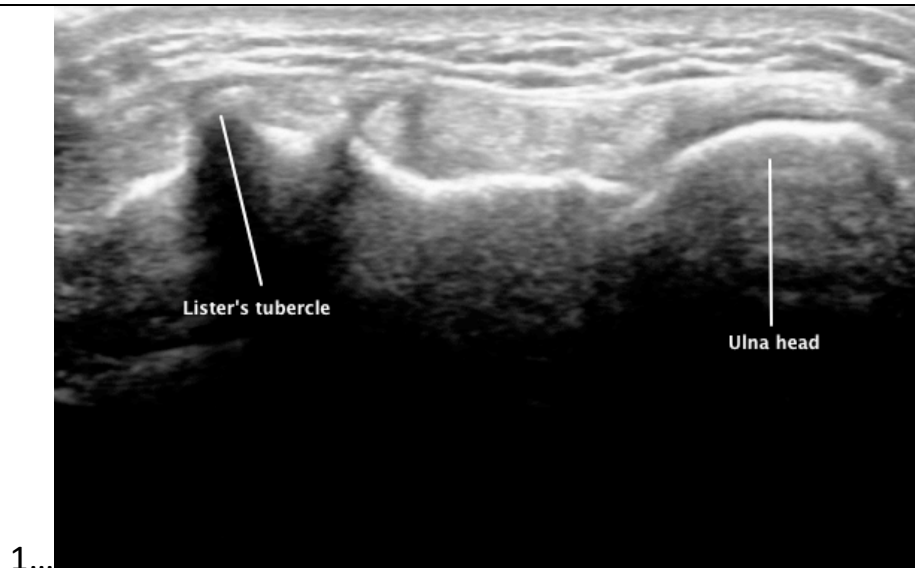


Figure 37: Anatomic anomalies seen in pronation using USI of the DRUJ

Pronation



Much less variation was seen in the pronated position with the ulna head consistently demonstrating a semi-circular shape. As with the supinated and neutral positions, differences in the shape of the Lister's tubercle was seen across participants

6.3 Interpretation of results

6.3.1 Mean translation values

The current study, using USI as an alternative method for assessing DRUJ translation in healthy individuals, produced similar mean values compared with those reported in previous literature. There has been no other study that has examined normal DRUJ translation using USI, to the author's knowledge. However, previous normative data has been established using either cadaver or CT studies. In the forearm neutral position the mean amount of ulna radial translation that occurred was 4.66mm which is consistent with the 4-6mm value reported in previous literature (Szabo, 2006; Tsai & Pakisma, 2009).

The effect of forearm position was investigated using USI as this is thought to cause translational adjustments in the DRUJ. Assessing various positions is also fundamentally important clinically, as functional positions often incorporate multitudinal degrees of forearm rotation. Maximal forearm supination produced a mean 0.67mm of volar translation compared to the neutral position. The opposite was found to occur with maximal forearm pronation, which was found to have a mean of 1.69mm of dorsal translation. Other studies that have investigated various measurement methods of DRUJ translation using CT, have failed to produce quantifiable measurements that were reliable. Our study supports the findings of Park & Kim (2008), with an analysis of 45 asymptomatic wrists using four different methods of CT analysis. The study by Park & Kim (2008) was primarily a reliability study and found that the subluxation ratio had the greatest within and between session repeatability compared to three other documented methods. Our study developed a technique based on the subluxation ratio that only required the dorsal aspect of the DRUJ to be visualised in the ultrasound image.

The results from the CT study by Park & Kim (2008) found that supination produced 14% difference in volar translation compared to neutral position. Similarly, our USI study produced a 14.37% difference. Pronation was found to produce slightly more translation in the dorsal direction with a difference of 36% compared to the neutral position. In the CT study by Park & Kim (2008), this was found to have a difference of 20%. Overall both studies can conclude that there is more translation with forearm pronation compared with supination. In addition, pronation is shown to

cause ulna radial translation in the dorsal sagittal plane compared to supination, which was found to cause volar translation.

Isometric gripping of a 1kg weight resulted in translation that increased more significantly in forearm supination than pronation, when compared to their equivalent non gripping positions. Supination was found to produce a mean of 0.22mm of dorsal translation compared to 0.07mm in pronation. Only one study that the author is aware of has examined the role of isometric gripping torque in DRUJ translation. A study by Tay et al. (2007) found that with maximal isometric pronation, translation of 0.13mm occurred. Maximal isometric gripping in supination was found to produce greater translation 0.51mm. Both our study results and the results produced by Tay et al. (2007) indicate that maximal isometric gripping in supination causes significantly more ulna radial translation than in pronation. An explanation for this may be that the DRUL's may be more efficient at stabilising the ulna head within the sigmoid notch compared to the PRUL's supporting the findings of several anatomy studies (Kihara, Short, Werner, Fortino, & Palmar, 1995; Stuart, et al., 2000; Szabo, 2006; Ward, et al., 2000). A significant disadvantage of the study produced by Tay et al. (2007) is the very small sample size of ten normal wrists, and could explain the higher values presented compared to the current USI study. Despite the small sample size, the study design was able to generate quantifiable and graded isometric gripping torques using a customised device. Also, the study by Tay et al. (2007) measured both dorsopalmar and distal to proximal translation of the ulna. These components provide useful information regarding the effect of defined loads on both DRUJ translation and ulna variance.

Future research using USI should aim to replicate these components in order to develop a better understanding of the DRUJ anatomy and also further investigate the diagnostic modality.

6.3.2 Repeatability

The current study demonstrated very good to excellent repeatability when measuring DRUJ translation on two separate occasions. Other than the position of forearm rotation there was no statistically significant difference between hand, left versus right, state or session. There are no other studies reviewed in the literature

that have investigated the repeatability or inter session repeatability of CT scanning methods of the DRUJ. The assessor in this study was blinded to measurements taken in the first session as all measurements were conducted once scanning had been completed. Therefore, there was no bias when taking or measuring the second session scans, which could influence the reliability results.

No significant difference in repeatability ICC was found between session, positions, state or hand. Non gripping supination was shown to have moderate to excellent repeatability between sessions. The only measurement found to be somewhat variable was gripping pronation. In the left hand this was shown to have good repeatability, whereas the right hand was the only measurement interpreted to have low repeatability. All other positions and states were interpreted to have good repeatability. Intra session repeatability was found to have values much higher than inter session analyses, as the Cronbach's alpha correlation measurement was interpreted as excellent across all positions and states.

The accuracy of USI as an imaging modality depends on several factors, which include sonographer expertise, variability of study designs, gold standards and equipment (Jacobson, 2009). It is therefore quite difficult to compare to other modalities such as MRI or CT (Jacobson, 2009). There have been some studies that have been reviewed and shown that USI is equivocal if not superior to MRI in diagnosing conditions that require joint movement or positioning to display pathologies (Jacobson, 2009). Unfortunately, most of these studies are small and have primarily investigated tears of the rotator cuff, Achilles tendon rupture, Peroneal tendon tears, anterior Talofibular ligament and Tibialis Posterior tendon tears (Jacobson, 2009).

One of the disadvantages with USI, as with other modalities, is the accuracy of imaging and quantifying distances due to operator dependency (Balint & Sturrock, 2001). Minimising variability of observers is essential for accuracy, as repeatability is determined based on several factors (Jacobson, 2009). Exclusive to USI, additional factors include appropriate transducer selection for the defined area, adequate anatomical knowledge to find and evaluate the structure in question, and recognise and adjust for artefacts such as anisotropy (Jacobson, 2009). Jacobson (2009),

reviewed many studies investigating inter-observer repeatability of musculoskeletal USI and suggest a direct relationship between years of experience and inter-observer variability exists. Although in this review three of the four studies found 'good' or 'very good' inter-observer agreement between non-experienced (less than six months) and experienced (five to fifteen years) examiners in the diagnosis of pathologies of the shoulder, rotator cuff and patella tendon (Jacobson, 2009).

The present study had excellent within session repeatability. The assessor in this study had a very high level of anatomical knowledge of the structures being examined, which is considered favourable when discussing repeatability of USI. The assessor had undertaken a short course in the techniques in relation to sonography and use of the Phillips iU22 ultrasound machine. One other study examining within session repeatability using USI, also found that within session errors were very low, regardless of the sonographer experience (Balint & Sturrock, 2001). The study by Balint & Sturrock (2001) supports that reliability may not solely dependent on the experience of the sonographer, but that quality of training is of relevant consideration (Jacobson, 2009). Overall, the current USI study and the study by Balint & Sturrock, (2001), have produced very high within session repeatability, indicating that both novice and experienced researchers can develop consistent imaging techniques.

One other study examining within session repeatability using CT produced high repeatability for measuring DRUJ translation (Lo, et al., 2001). Although this study used the RUR method rather than the RASR method reported in the present USI study. The CT study using the RUR method reported a correlation value of 0.89, similarly in the present study the Cronbach's alpha value was consistently over 0.9 for all positions and states tested. Overall both USI and some CT methods can produce consistently high within and between session repeatability values. The results of these studies indicate that neither modality is superior in regards to internal consistency, although further direct comparisons between CT and USI should be made in future research.

Our study produced good repeatability and between session repeatability due to sufficient anatomical knowledge and practical experience of the assessor. Future studies aimed at evaluating the accuracy of USI, particularly in specialised joints such as the DRUJ, should continue to consider education and experience of sonographer or

researcher (Jacobson, 2009). Maintaining a high standard of practice is considered to be vital to the success of musculoskeletal USI (Jacobson, 2009). Larger multi-centre trials using USI in direct comparison with MRI and CT will need to ensure that the testing sonographers develop a prior knowledge of the biomechanics and pathomechanics of the DRUJ. This will have a contiguous effect on the resulting repeatability and accuracy of the images produced. On the other hand in a clinical context, imaging performed by clinicians can be focused and immediately impact on patient care (Jacobson, 2009). These issues highlight the necessity to include multiple health professionals to communicate and establish relationships between sonography experts in future research and ultimately in clinical scenarios.

6.3.3 Validity

The overall results of this study are comparable to the study by Henmi et al. (2007), which measured both normal and pathological DRUJ's using the RASR method with CT. Our USI study produced a slightly higher mean of 0.239 and a much higher standard deviation of 0.44 compared to a mean of 0.106 and standard deviation of 0.072 observed in healthy wrists by Henmi et al. (2007). Measurements from the first session in the present USI study were chosen. As there was no variation found between sessions, it was thought only the first set of measurements examining non gripping pronation from were sufficient to calculate a mean and standard deviation and make comparisons to the Henmi et al. (2007) study.

There were several methodological differences between the two studies, which may explain the small difference between the two means. The CT study by Henmi et al, (2007), had a very low sample size of ten compared to 46 in the current USI study. Studies with larger samples are known to have more accuracy and repeatability than those of smaller sample sizes, and may reduce the power of the earlier CT study (Field, 2005).

Positioning of participants varied between the two studies, although both studies did measure the RASR in full maximal forearm pronation. In the study by Henmi et al. (2007), participants were positioned in prone lying with the shoulder above the head in flexion, and elbow extended. Our study used a sitting position with shoulder neutral and the elbow flexed at 90°. Changes in elbow position is known to

cause variation in regards to DRUJ biomechanics, with increasing elbow extension causing the centre of rotation to shift palmarly and ulnarly (Fu, et al., 2009).

Further studies comparing USI to CT using the RASR method should be conducted where the same participants and standardised positioning are utilised. This will assist in making direct comparisons of validity of USI as a diagnostic tool to assess DRUJ translation. In addition, clinically unstable patients should be assessed with both methods to further investigate the differences between the two methods.

6.4 Limitations of the Study

There is some debate in the literature regarding the ability for USI to access deeper structures and provide high resolution images (Kijowski & De Smet, 2006). The inability for USI to provide extensive evaluation and information regarding intra-articular structures may be more problematic in deeper joints such as the hip (Kijowski & De Smet, 2006), and therefore not a valid limitation of this study. In addition, the DRUJ is considered a fairly superficial joint and overlying tendons, nerves and muscles are in close proximity to the joint space. Furthermore, there is little muscle coverage over the dorsal aspect of the DRUJ, enhancing the ability to obtain adequate images of bony landmarks and joint space associated with the joint.

One major limitation of USI imaging is operator dependency due to variable applied pressure, using a free-hand technique which may affect reproducibility (Klauser & Peetrons, 2010). Future studies could consider moderation of pressure exerted by the probe in order to avoid overly high or low pressures. Although this may not be as critical when examining bone or stabilised joints, due to their relatively lower strain values compared with soft tissues (Klauser & Peetrons, 2010). Klauser & Peetrons, (2010), suggest using a visual indicator scale on the ultrasound machine itself, so when pressure increases or decreases past a certain level the pattern of elasticity can start to change drastically.

In this study the method of capturing the images and the measurement process was not randomised and this may have contributed to ordered effects where the participant may perform differently for certain measurements or the assessor may measure differently. However early in piloting this was not considered to occur.

Ulna variance was not able to be measured using this method as USI can not take longitudinal images of the radius and ulna. This would have been a useful measurement and would have provided a more complete understanding of the relationship between DRUJ translation and ulna variance in a healthy population. It is suggested that positive ulna variance is associated with damage to the stabilising structures of the DRUJ and stability of the joint {Shen, 2005 #36}. With the advances in USI technology there may be a possibility that future research could examine this relationship and also compare to a pathological population.

6.5 Clinical, Socio-economic and Research Implications

The use of USI for assessing DRUJ translation, and potentially pathological translation may provide us with an improved understanding of DRUJ biomechanics in both healthy and injured populations. This knowledge is pertinent to making decisions regarding treatment such as positions to splint, muscle education and strengthening, and timely return to functional activity. Clinical instability poses several challenges in regards to treatment strategies and also the decision between conservative or surgical management. Consequently the use of USI over other traditional methods of imaging such as CT or MRI would reduce diagnostic costs, lead to improved rehabilitation outcomes and may help avoid invasive surgical procedures.

USI can also be used as a rehabilitative tool for restoring muscle control and co-ordination, enhancing motor learning and performance through biofeedback mechanisms (Henry & Teyhen, 2007). Rehabilitative ultrasound imaging (RUSI) could be used for both assessment and management of early stage dynamic instability of the DRUJ. Strengthening of the DRUJ stabilisers such as PQ, flexor carpi ulnaris (FCU) and ECU may provide dynamic tensioning of the ulna head inside the sigmoid notch (Bader, et al., 2008; Tsai & Pakisma, 2009). Clinically, RUSI could be used as a biofeedback tool during strengthening of PQ, FCU & ECU, as an objective measurement pre and post strengthening treatment sessions or to examine the success of a series of treatments such splinting and strengthening.

On average the cost of conducting and interpreting an ultrasound scan is 30% of the cost it would take for the equivalent MRI scan (Jacobson, 2009). Also, in the time it would take for an MRI scan to be analysed it is estimated that 2-3 ultrasound scans can be studied and interpreted (Jacobson, 2009). These factors have extensive financial effects at a local and national level (Jacobson, 2009). A study by Parker, Nazarian & Carrino (2008), has calculated a cost saving of 6.9 billion from 2006 to 2020 based on data obtained over one year. Approximately 45% of primary diagnoses and 31% of all musculoskeletal diagnoses made with MRI could have been made with USI, after reviewing indications for each particular study (Parker, et al., 2008). The combination of increased usage of USI and cost benefits may have immense implications in health care decision making and reform agreements at a government

level (Jacobson, 2009). In New Zealand, the Accident Compensation Corporation (ACC) spent over 123 million dollars on high technology musculoskeletal medical imaging such as MRI and CT, whereas 70 million was spent on radiology including both X-ray and USI (ACC, 2012).

The costs of the machines themselves vary greatly with an ultrasound machine estimated to cost around US\$60,000 compared with US\$2,000,000 for an MRI machine (Jacobson, 2009). Additionally, considering the costs of servicing and maintenance for an ultrasound machine is US\$15,000 compared to US\$100,000 for MRI, the economical benefit of USI is unparalleled (Jacobson, 2009).

Future research should first be aimed at examining a larger normal population as a multi-centre trial, this would enable further validation of the efficacy of USI in a non-symptomatic population. Secondly trials examining patients with mild through to severe DRUJ instability should be assessed with results being compared to equivalent CT scans and USI data. Lastly supplementary uses such as RUSI and other clinical applications should be investigating. Further studies in these areas would help support the use of developing a clinically acceptable diagnostic and biofeedback tool, improving the diagnosis and treatment in patients with DRUJ instability.

CHAPTER SEVEN - CONCLUSION

Injuries to the wrist and hand can include a wide variety of pathologies to bones, joints, ligaments and muscles that may occur in isolation but more commonly in combination (Heuck, et al., 1997). When assessing trauma or degenerative related pathological tissues by radiological analysis, a profound understanding of the main principles of anatomy and physiologic movement is essential (Heuck, et al., 1997). Imaging modalities that can achieve proper detection, localisation and characterisation of a suspected injury will benefit both clinician and patient (Heuck, et al., 1997).

The main advantage of USI is the ability to perform multiplanar, real time dynamic imaging without ionising radiation, promoting its use as a first line imaging modality of soft tissue trauma (Luck, 2008; Mankad, Hoey, Grainger, & Barron, 2008). Secondary advantages include high accessibility, low cost and the ability to compare to an asymptomatic side (Luck, 2008). However, there are disadvantages which include operator dependency along with the need for examiner's to have a highly detailed knowledge of relevant anatomy (Luck, 2008).

Customary beliefs that USI largely has applications in only detecting changes in soft tissue structures are fast becoming dismissed, with new recognition that USI may play a role in the evaluation of all tissues including cortical bone surfaces and joints (Adler, 1999). It is increasingly important for the radiological, surgical and clinical communities to become familiar with new advances in USI not only for economic reasons, but the rich complement of future research and applications to clinical decision making that is offered (Adler, 1999).

This study has shown that USI can reliably detect translatory movement of the DRUJ in healthy participants. It supports the role of USI in future musculoskeletal applications, which could significantly impact clinical diagnosis and therapy. Ideally USI will have a complementary role with other imaging modalities, with the most appropriate imaging test selected based on clinical findings and sound reasoning

References

- Adams, B. D. (1993). Effects of radial deformity in distal radioulnar joint mechanics. *The Journal of Hand Surgery*, 18(3), 492-498.
- Adler, R. S. (1999). Future and new developments in musculoskeletal ultrasound *Radiologic Clinics of North America*, 37(4), 623-631.
- Bader, J., Boland, M., Uhl, T., & Pienkowski, D. (2008). The influence of fifteen muscles on the distal radioulnar joint loading. A biomechanical model. University of Kentucky.
- Baeyens, J. P., Van Glabbeek, F., Goossens, M., Gielen, J., Van Roy, P., & Clarys, J.-P. (2006). In vivo 3D arthokinematics of proximal and distal radioulnar joints during active pronation and supination. *Clinical Biomechanics*, 21, 9-12.
- Balint, P. V., & Sturrock, R. D. (2001). Intraobserver repeatability and interobserver reproducibility in musculoskeletal ultrasound imaging. *Clinical and Experimental Rheumatology*, 19, 89-92.
- Bianchi, S., Martinoli, C., Sureda, D., & Rizzatto, G. (2001). Ultrasound of the hand. *European Journal of Ultrasound*, 14, 29-34.
- Borsa, P. A., Jacobson, J. A., Scibek, J. S., & Dover, G. C. (2005). Comparison of dynamic sonography to stress radiography for assessing glenohumeral laxity in asymptomatic shoulders. *The American Journal of Sports Medicine*, 33(5), 734-741.
- Burk, D. L., Karasick, D., & Wechsler, R. J. (1991). Imaging of the distal radioulnar joint *Hand Clinics*, 7(2), 263-275.
- Cheng, S. C., Hulse, D., Fairburn, K. J., Clarke, M., & Wallace, W. A. (2008). Comparison of dynamic ultrasound and stress radiology for assessment of inferior glenohumeral laxity in asymptomatic shoulders. *Skeletal Radiology*, 37, 161-168.
- Chiang, C.-C., Chang, M.-C., Lin, J., Liu, Y., & Lo, W.-H. (1998). Computerised tomography in the diagnosis of subluxation of the distal radioulnar joint *Chinese Medical Journal*, 61(12), 708-715.
- Easton, V. J., & McColl, J. H. (2012). Paired data, correlation and regression. Retrieved 14th April, 2012, from http://www.stats.gla.ac.uk/steps/glossary/paired_data.html#resid
- Elias, F. M., Birman, E. G., Matsuda, C. K., Oliviera, I. R., & Jorge, W. A. (2006). Ultrasonographic findings in normal temporomandibular joints. *Brazilian Oral Research*, 20(1), 25-32.
- Ellis, R. D., Hing, W. A., & McNair, P. J. (2012). Comparison of longitudinal nerve movement with different mobilization exercises: An in vivo study utilizing ultrasound imaging. *Journal of Orthopaedic and Sports Physical Therapy*, 42(8), 667-675.
- Faber, K. J., Iordache, S., & Grewal, R. (2010). magnetic Resonance Imaging for Ulnar Wrist Pain. *The Journal of Hand Surgery*, 35A, 303-307.
- Fess, E. E., & Moran, C. A. (1981). Clinical assessment recommendations.

- Field, A. (2005). *Discovering statistics using SPSS* (2nd ed.). London: Sage publications.
- Fu, E., Li, G., Souer, J. S., Lozano-Calderon, S., Herndon, J. H., Jupiter, J. B., et al. (2009). Elbow position affects distal radioulnar joint kinematics. *The Journal of Hand Surgery*, 34(7), 1261-1268.
- Garrigues, G. E., Sabesan, V., & Aldridge, J. M. (2008). Acute distal radioulnar joint instability. *Journal of Surgical Orthopaedic Advances*, 17(4), 262-266.
- George, D., & Mallery, P. (2003). *SPSS for Windows step by step: A simple guide and reference* (4th ed.). Boston: Allyn & Bacon.
- Gong, H. S., Roh, Y. W., Oh, J. H., Lee, Y. H., Chung, M. S., & Baek, G. H. (2009). Computed tomographic assessment of reduction of the distal radioulnar joint by gradual lengthening of the radius. *The Journal of Hand Surgery*, 34E(3), 391-396.
- Henmi, S., Yonenobu, K., Akita, S., Kuroda, Y., & Yoshida, K. (2007). Diagnosis of distal radioulnar joint subluxation in patients with rheumatoid wrist by computed tomography. *Modern Rheumatology*, 17, 279-282.
- Henry, S. M., & Teyhen, D. S. (2007). Ultrasound Imaging as a feedback tool in the rehabilitation of trunk muscle dysfunction for people with low back pain. *Journal of Orthopaedic and Sports Physical Therapy*, 37(10), 627-634.
- Heuck, A., Bonel, H., Stabler, A., & Schmitt, R. (1997). Imaging in sports medicine: hand and wrist. *European Journal of Radiology*, 26, 2-15.
- Jacobson, J. A. (2009). Musculoskeletal Ultrasound: Focused Impact on MRI. *American Journal of Roentgenology*, 193, 619-627.
- Jaffe, R., Chidgey, L. K., & LaStayo, P. C. (1996). The distal radioulnar joint: Anatomy and management of disorders. *Journal of Hand Therapy*, 2(2), 129-138.
- Jones, M. H., England, S. J., Muwanga, C. L., & Hildreth, T. (2000). The use of ultrasound in the diagnosis of injuries of the ulnar collateral ligament of the thumb. *Journal Of Hand Surgery*, 25B(1), 29-32.
- Kihara, H., Short, W., Werner, F. W., Fortino, M. D., & Palmar, A. K. (1995). The stabilising mechanism of the distal radioulnar joint during pronation and supination. *The Journal of Hand Surgery*, 20(6), 930-936.
- Kijowski, R., & De Smet, A. A. (2006). The role of ultrasound in the evaluation of sports medicine injuries. *Clinics in Sports Medicine*, 25, 569-590.
- Kim, J. P., & Park, M. J. (2008). Assessment of distal radioulnar joint instability after distal radius fracture: comparison of computed tomography and clinical examination results. *Journal Of Hand Surgery*, 33(9), 1486-1492.
- King, G., McMurty, R. Y., Rubenstein, J. D., & Gertzbein, S. D. (1986). Kinematics of the distal radioulnar joint. *The Journal of Hand Surgery*, 11(6), 798-804.

- King, G., McMurty, R. Y., Rubenstein, J. D., & Ogston, N. G. (1986). Computerised tomography of the distal radioulnar joint: Correlation with ligamentous pathology in a cadaveric model. *Journal Of Hand Surgery*, 11(5), 711-717.
- Klauser, A. S., & Peetrons, P. (2010). Developments in musculoskeletal ultrasound and clinical applications. *Skeletal Radiology*, 39, 1061-1071.
- Kleinman, W. B. (2007). Stability of the Distal Radioulna Joint: Biomechanics, Pathophysiology, Physical Diagnosis and Restoration of Function: What We Have Learned in 25 Years *The Journal of Hand Surgery*, 32A(7), 1086-1106.
- Lento, P. H., & Primack, S. (2008). Advances and utility of diagnostic ultrasound in musculoskeletal medicine. *Current Reviews in Musculoskeletal Medicine*, 1, 24-31.
- Lindau, T., Adlercreutz, C., & Aspenberg, P. (2000). Peripheral tears of the triangular fibrocartilage complex cause distal radioulnar joint instability after distal radius fractures. *The Journal of Hand Surgery*, 25(3), 464-468.
- Linscheid, R. L. (1992). Biomechanics of the distal radioulnar joint. *Clinical Orthopaedics and Related Research*, 275, 46-55.
- Lo, I. K. Y., MacDermid, J. C., Bennett, J. D., Bogoch, G. J. W., & King, G. J. W. (2001). The radioulnar ratio: A new method of quantifying distal radioulnar subluxation. *The Journal of Hand Surgery*, 26(2), 236-243.
- Luck, L. (2008). Musculoskeletal Ultrasound: Principles and Advances. *Radiologic Clinics of North America*, 46, 515-533.
- Mackin, E. J., Callahan, A. D., Skirven, T. M., Schneider, L. H., Osterman, A. L., & Hunter, J. M. (2005). *Rehabilitation of the hand and upper extremity* (5th ed.). Philadelphia: Mosby.
- Mankad, K., Hoey, E., Grainger, A. J., & Barron, D. A. (2008). Trauma musculoskeletal ultrasound. *Emergency Radiology*, 15, 83-89.
- McNally, E. G. (2011). The development and clinical applications of musculoskeletal ultrasound. *Skeletal Radiology*, 40, 1223-1231.
- Mikic, Z. D. (1989). Detailed anatomy of the articular disc of the distal radioulnar joint. *Clinical Orthopaedics*, 245, 123-132.
- Mino, D. E., Palmer, A. K., & Levinsohn, M. (1983). The role of radiography and computerised tomography in the diagnosis of subluxation and dislocation of the distal radioulnar joint. *The Journal of Hand Surgery*, 8(1), 23-31.
- Moore, D. C., Hogan, K. A., Crisco, J. J., Akelman, E., DaSilva, M. F., & Weiss, A.-P. C. (2002). Three-Dimensional in vivo kinematics of the distal radioulnar joint in malunited distal radius fractures. *The Journal of Hand Surgery*, 27(2), 233-242.
- Mulford, J. S., & Axelrod, T. S. (2010). Traumatic injuries to the distal radioulnar joint. *Hand Clinics*, 26(1), 155-163.
- Nakamura, R., Horii, E., Imaeda, T., & Nakao, E. (1996). Criteria for diagnosing distal radioulnar joint subluxation by computed tomography. *Skeletal Radiology*, 25, 649-653.

- Nakamura, T., Yabe, Y., Horuichi, Y., & Yamazaki, N. (1999). In vivo motion analysis of forearm rotation utilizing magnetic resonance imaging. *Clinical Biomechanics*, 14, 315-320.
- Nathan, R., & Schneider, L. H. (1991). Classification of distal radioulnar joint disorders. *Hand Clinics*, 7(2), 239-247.
- Nicolaidis, S. C., Hildreth, D. H., & Lichtman, D. M. (2000). Acute injuries of the distal radioulnar joint. *Hand Clinics*, 16(3), 449-459.
- Ozer, K., & Schecker, L. R. (2006). Distal radioulnar joint problems and treatment options *Orthopedics*, 29(1), 38-49.
- Park, M. J., & Kim, J. P. (2008). Reliability and normal values of various computed tomography methods for quantifying distal radioulnar joint translation. *The Journal of Bone and Joint Surgery*, 90, 145-153.
- Parker, I., Nazarian, L. N., & Carrino, J. A. (2008). Musculoskeletal Imaging: Medicare use, cost and potential for cost substitution. *Journal American College of Radiology*, 5, 182-188.
- Pirela-Cruz, M. A., Goll, S. R., Klug, M., & Windler, D. (1991). Stress computed tomography analysis of the distal radioulnar joint: A diagnostic tool for determining translational motion. *The Journal of Hand Surgery*, 16(1), 75-82.
- Portney, L., & Watkins, M. (1993). *Foundations of Clinical Research: Applications to Practice*. Norwalk: Appleton & Lange.
- Sasaki, J., Takahara, M., Ogino, T., Kashiwa, H., Ishigaki, D., & Kanauchi, Y. (2002). Ultrasonographic Assessment of the Ulnar Collateral Ligament and Medial Ligament Laxity in College Baseball Players. *The Journal of Bone and Joint Surgery*, 84A(4), 525-531.
- Shen, J., Papadonikolakis, A., Garrett, J. P., Davis, S. M., & Ruch, D. S. (2005). Ulnar positive variance as a predictor of distal radioulnar joint ligament disruption. *The Journal of Hand Surgery*, 30(6), 1172-1177.
- Stuart, P. C., Berger, R. A., Linscheid, R. L., An, K. N., & Rochester, M. N. (2000). The dorsopalmar stability of the distal radioulnar joint. *The Journal of Hand Surgery*, 25(4), 689-699.
- Szabo, R. M. (2006). Distal radioulnar joint instability *The Journal of Bone and Joint Surgery*, 88(4), 884-894.
- Tay, S. C., Berger, R. A., Tomita, K., Amrami, K. K., & An, K. N. (2007). In vivo three dimensional displacement of the distal radioulnar joint during resisted forearm rotation. *The Journal of Hand Surgery*, 32(4), 450-458.
- Tay, S. C., Van Riet, R., Kazunari, T., Koff, M. F., Amrami, K. K., An, K. N., et al. (2008). A method for in vivo kinematic analysis of the forearm. *Journal of Biomechanics*, 41, 56-62.
- Tolat, A. R., Stanley, J. K., & Trail, I. A. (1996). A cadaveric study of the anatomy and stability of the distal radioulnar joint in the coronal and transverse planes. *Journal Of Hand Surgery*, 21(5), 587-594.

- Tsai, P. C., & Pakisma, D. O. (2009). The distal radioulnar joint. *Bulletin of the NYU Hospital for Joint Diseases*, 67(1), 90-96.
- Wang, S.-C., Chhem, R. K., Cardinal, E., & Cho, K.-H. (1999). Joint Sonography. *Radiologic Clinics of North America*, 37(4), 653-668.
- Ward, L. D., Ambrose, C. G., Masson, M. V., & Levaro, F. (2000). The role of distal radioulnar ligaments, interosseous membrane and joint capsule in distal radioulnar joint stability. *The Journal of Hand Surgery*, 25(2), 431-351.
- Watanabe, H., Berger, R. A., Berglund, L. J., Zobitz, M. E., An, K. N., & Rochester, M. N. (2005). Contribution of the interosseous membrane to distal radioulnar joint constraint. *Journal Of Hand Surgery*, 30(6), 1164-1171.

APPENDIX A



MEMORANDUM

Auckland University of Technology Ethics Committee (AUTEC)

To: Wayne Hing
From: **Madeline Banda** Executive Secretary, AUTEC
Date: 23 December 2010
Subject: Ethics Application Number 10/262 **Is ultrasound a valid and reliable method for assessing translation of the distal radioulnar joint?**

Dear Wayne

Thank you for providing written evidence as requested. I am pleased to advise that it satisfies the points raised by the Auckland University of Technology Ethics Committee (AUTEC) at their meeting on 8 November 2010 and that I have approved your ethics application. This delegated approval is made in accordance with section 5.3.2.3 of AUTEC's *Applying for Ethics Approval: Guidelines and Procedures* and is subject to endorsement at AUTEC's meeting on 24 January 2011.

Your ethics application is approved for a period of three years until 23 December 2013.

I advise that as part of the ethics approval process, you are required to submit the following to AUTEC:

- A brief annual progress report using form EA2, which is available online through <http://www.aut.ac.nz/research/research-ethics/ethics>. When necessary this form may also be used to request an extension of the approval at least one month prior to its expiry on 23 December 2013;
- A brief report on the status of the project using form EA3, which is available online through <http://www.aut.ac.nz/research/research-ethics/ethics>. This report is to be submitted either when the approval expires on 23 December 2013 or on completion of the project, whichever comes sooner;

It is a condition of approval that AUTEC is notified of any adverse events or if the research does not commence. AUTEC approval needs to be sought for any alteration to the research, including any alteration of or addition to any documents that are provided to participants. You are reminded that, as applicant, you are responsible for ensuring that research undertaken under this approval occurs within the parameters outlined in the approved application.

Please note that AUTECH grants ethical approval only. If you require management approval from an institution or organisation for your research, then you will need to make the arrangements necessary to obtain this.

When communicating with us about this application, we ask that you use the application number and study title to enable us to provide you with prompt service. Should you have any further enquiries regarding this matter, you are welcome to contact Charles Grinter, Ethics Coordinator, by email at ethics@aut.ac.nz or by telephone on 921 9999 at extension 8860.

On behalf of the AUTECH and myself, I wish you success with your research and look forward to reading about it in your reports.

Yours sincerely

A handwritten signature in black ink, appearing to read 'M. Banda'.

Madeline Banda

Executive Secretary

Auckland University of Technology Ethics Committee

Participant Information Sheet



Date Information Sheet Produced:

15/09/2010

Project Title

Is ultrasound a valid and reliable method for assessing translation of the distal radioulnar joint?

An Invitation

Thank you for considering to participate in my research project. My name is Christie Oldfield and I am a New Zealand trained Physiotherapist, gaining my BHSc (physiotherapy) qualification in 2004 at AUT. After working in private practice for 3 years I decided that my interests primarily concentrated on forearm and hand injuries, and trained in hand and upper limb therapy in 2008. I started working at Hands out West in 2007, whilst studying at AUT and gaining the status of a New Zealand registered hand therapist in 2009. Through my study at AUT I became interested in research and am currently writing my thesis in collaboration with this research project to gain my Masters in Health Science (Rehabilitation).

If you wish to participate in this research project you may refuse to answer any particular question, and to withdraw from the study up until the time of submission. You are encouraged to ask any further questions about the study that occurs to you during your participation.

What is the purpose of this research?

The purpose of this study is to investigate the normal amount of movement that occurs between the radius and ulna bones (lower forearm bones) at the wrist using ultrasound imaging. The data collected will form an opinion on whether this is a reliable and valid tool to use for measuring the amount of movement between the bones. This will be written in a thesis and also maybe written up as a publication in a journal. The research will provide information for future research aimed at the examination of an injured population and also will assist further development of a useful tool for patients in a clinical setting.

What will happen in this research?

You will be required to donate 2 hours of their time in total. On two separate occasions (separated by approximately 7-14 days) you will be required for one hour to attend the AUT musculoskeletal imaging unit and have both your wrists scanned three times in three different positions. Wrists will then be re-scanned while you hold onto a weight.

What are the discomforts and risks?

The procedure will not cause you any pain or discomfort and is safe.

How will these discomforts and risks be alleviated?

As the procedure is safe, there is no expectation that any discomfort or risks will be experienced. However, the researcher throughout testing at all times will monitor you

What are the benefits?

The use of ultrasound imaging to assess stability of forearm and wrist joints may provide an alternative method to computerised tomography (CT) scans, which are costly and subject patients to high levels of radiation exposure.

What compensation is available for injury or negligence?

In the unlikely event of a physical injury as a result of your participation in this study, rehabilitation and compensation for injury by accident may be available from the Accident Compensation Corporation, providing the incident details satisfy the requirements of the law and the Corporation's regulations.

How will my privacy be protected?

Your contact details and information are confidential and will not be given to any other party other than the Principal researcher & supervisor. All information obtained will be kept in a secure, locked location within the Health & Rehabilitation Research Institute of AUT University.

What are the costs of participating in this research?

Apart from your time there is no direct costs involved. The maximum amount of time you will need to give will be two hours (one hour on two separate occasions).

What opportunity do I have to consider this invitation?

Interest to participate in this study will be required within 3 months of the research project being initiated

How do I agree to participate in this research?

By reading and signing the consent form given with this information sheet

Will I receive feedback on the results of this research?

You will be given access to a summary of the findings from the study, when it is concluded and when requested

What do I do if I have concerns about this research?

Any concerns regarding the nature of this project should be notified in the first instance to the Project Supervisor, Dr Wayne Hing, whing@aut.ac.nz, Ph 09 9219999 ext 7800

Concerns regarding the conduct of the research should be notified to the Executive Secretary, AUTEC, Madeline Banda, madeline.banda@aut.ac.nz, Ph 09 921 9999 ext 8044.

Whom do I contact for further information about this research?**Researcher Contact Details:**

Christie Oldfield, c/o Hands Out West Ltd, 38 Lincoln Rd, Henderson, Auckland. Work ph. 09 8386510

Project Supervisor Contact Details:

Dr Wayne Hing, AUT University School of Rehabilitation & Occupation Studies, Auckland, Ph 09 9219999 x7800

Approved by the Auckland University of Technology Ethics Committee on 23/12/2010, AUTEC Reference number 10/262.

Consent to Participation in Research

Title of Project:

Is ultrasound a valid and reliable method for assessing translation of the distal radioulnar joint?

Researcher:

Christie Hornell

-
- I have read and understood the information provided about this research project
 - I have had an opportunity to ask questions and to have them answered.
 - I understand that I may withdraw myself or any information that I have provided for this project at any time prior to completion of data collection, without being disadvantaged in any way.
 - If I withdraw, I understand that all relevant data, or parts thereof, will be destroyed.
 - I agree to take part in this research.
 - I wish to receive a copy of the report from the research: tick one: Yes ☐ No ☐

Participant signature:

Participant name:

Participant Contact Details (if appropriate):

.....
.....
.....
.....

Date:

Approved by the Auckland University of Technology Ethics Committee on
23/12/2010 AUTECH Reference number 10/262 Note: The Participant should retain a
copy of this form.

APPENDIX D

Table 7: Current CT literature for assessing DRUJ kinematics

Study	Purpose	Participants	Method	Measurement & DRUJ Bony landmarks used	Position	Results
(King, McMurty, Rubenstein, & Ogston, 1986)	To examine both the normal kinematics of the DRUJ and the effect of sequential division of supporting structures	7 fresh cadaver extremities	Anteroposterior and lateral CT scan scout film images centred on the DRUJ. CT images were magnified to computer 1.5x larger to measure dorsal, palmar and lateral displacement of the ulna relative to the radius	Radius and ulna. No specific landmarks.	90° supination, 45° supination Neutral 45° pronation 90° pronation.	Palmar subluxation of ulna; 90° supination – 8.8% (+/- 3.1) 45° supination – 4.2% (+/- 2.1) Neutral – 3.7% (+/- 2.1) 45° pronation – 2.9% (+/- 2.2) 90° pronation – 10.7% (+/- 2.6) Dorsal subluxation of ulna; 90° supination – 2.2% (+/- 1.5) 45° supination – 2.3% (+/- 0.9) Neutral – 3.7% (+/- 2.9) 45° pronation – 0.4% (+/- 0.4) 90° pronation – 1.6% (+/- 1.3)
(Kim & Park, 2008)	To compare CT and clinical stress test findings in terms of assessment of the DRUJ instability after distal radius fracture	34 patients with a healed distal radius fracture (mean = 18 months post)	CT scans 3mm intervals injured and uninjured sides Three CT methods (radioulnar line (RUL) method, epicentre method and radioulnar ratio (RUR) method) assessed and compared with clinical stress test findings. Stress test; Examiner applies volar and dorsal translation of the ulna with the radius fixed with the other hand in forearm neutral.	<u>RUL method</u> ; Dorsal border of radius and ulna, volar border of radius, ulna head <u>Epicentre method</u> ; Centre of ulna head and styloid, dorsal and volar margins of the sigmoid notch <u>RUR method</u> ; Centre of ulna head, volar and dorsal margins of sigmoid notch	Shoulder adduction and elbow 90 flexion. Forearm at 70° supination, neutral and 70° pronation	Uninjured wrist <u>RUL method</u> ; Pronation 0.15 , neutral -0.06 , supination -0.10 <u>Epicentre method</u> ; Pronation -0.01 , neutral 0.07 , supination 0.10 <u>RUR method</u> ; Pronation 0.63 , neutral 0.48 , supination 0.43 Injured Wrist <u>Radioulnar line method</u> ; Pronation 0.11 , neutral -0.13 , supination -0.24 <u>Epicentre method</u> ; Pronation -0.01 , neutral -0.01 , supination 0.00 <u>Radioulnar ratio method</u> ; Pronation 0.60 , neutral 0.41 , supination 0.34
(Henmi, et al., 2007)	Compare a new method, the rheumatoid arthritis (RA) subluxation ratio with the modified RUL method for DRUJ subluxation	35 patients with RA and severe DRUJ damage post extensor tendon surgery (2003-2005). Also 10 healthy volunteers	CT images from a multidetector row scanner. 3D volume scan of hand and wrist and then 2D axial images of the distal radius reconstructed	<u>RA subluxation ratio</u> ; Lister's tubercle to ulnar aspect of radius, dorsal ulnar <u>Modified RUL</u> ; Dorsal borders of the radius and ulnar, volar borders of the ulnar and radial margins of the radius	Supine, arm elevated above the head and forearm in maximum pronation	<u>RA subluxation ratio</u> : mean = 0.376 in RA patients and mean = 0.106 in healthy volunteers. In RA patients non tendon rupture group mean = 0.333 and rupture group mean = 0.444 <u>Modified RUL</u> : 31 out of 35 wrists classified as no subluxation present.

Study	Purpose	Participants	Method	Measurement & DRUJ Bony landmarks used	Position	Results
(Lo, et al., 2001)	To compare the validity of the RUR method with 3 other methods for assessing subluxation of the DRUJ	13 participants with normal wrists, 6 cadaver specimens and 9 RA patients with DRUJ involvement	5 stages of evaluation: <u>Stage 1:</u> Normal patient population- Serial CT scans, Each image measured with each of the 4 methods. <u>Stage 2:</u> Evaluation of cadaver specimens. CT images magnified 1.5x and assessed using the 4 different methods <u>Stage 3:</u> Evaluation of cadaver specimens above with sequential division of stabilising structures. CT scans as above after division of 1. DRUL 2. PRUL 3. TFC 4. ECU subsheath 5. Distal portion of the interosseous membrane 6. Proximal interosseous membrane 7. PQ <u>Stage 4:</u> Evaluation of a RA population. CT scans as described in stage 1.	As described by (Kim & Park, 2008) for the radioulnar line method, epicentre method and radioulnar ratio method. Also used the congruency method; arc of ulna head and arc of sigmoid notch (this method was abandoned during the study due to low repeatability)	<u>Stage 1:</u> Prone, DRUJ measured with forearm in full pronation, neutral and full supination <u>Stage 2:</u> Upper humerus mounted with elbow 90. DRUJ measured with 90 supination, neutral and 90 pronation <u>Stage 3:</u> As for stage 2. <u>Stage 4:</u> As for stage 1.	<u>Stage 1:</u> RUL method- 8/13 patients unstable (6 had 10% displacement, 2 had 25% displacement) Epicentre method – 1 patient 25% displacement RUR method – all patients considered within normal range <u>Stage 2:</u> RUL method – 4/6 patients less than 15% subluxation Epicentre & RUR method 5/6 considered normal DRUJ stability <u>Stage 3:</u> RUR method able to detect subluxation 2 stages earlier than other methods. DRUJ subluxation evident in pronation reduced in supination <u>Stage 4:</u> RUL method 8/11 wrists considered subluxed (3 had >25% subluxation) Epicentre method – 9/11 wrist abnormal RUR method – All considered abnormal RUR also proved to have high intraobserver repeatability (0.89) and interobserver repeatability (0.94)
(Tay, et al., 2007)	To quantify the in vivo displacement of the normal DRUJ in 3 dimensions during resisted rotational torque	10 normal volunteers	Bilateral CT scans of forearms and wrist whilst participants grip the vertical handle of a patented custom apparatus to maintain the position of the wrist and forearm. Torque cells attached to handles could be generated to 6 settings (5,10, 20, 40, 60 & 80in.lb). When torque is achieved an orange LED light is triggered. CT scans were taken in 3 positions of forearm rotation	Ct images imported into analyse 7.0 for data analysis. The ulna fovea was used against an x-y-z transformation matrix to measure dorsal and palmar translation	Maximum supination, maximum pronation and untorqued control	<u>Mean displacement of ulna fovea:</u> Max isometric pronation 3.09mm (+/-0.94) Max isometric supination 2.17mm (+/-1.55) <u>Dorsopalmar (X axis) displacement ulna fovea:</u> Max isometric pronation -0.13mm (+/-2.07) Max isometric supination 0.51mm (+/-1.79) Indicating dorsal displacement in pronation and palmar displacement in supination Z component displacement: Max isometric pronation -0.23mm (+/-2.52) Max isometric supination -0.44mm (+/-1.57) Indicating ulna variance ↑ during both actions

Study	Purpose	Participants	Method	Measurement & DRUJ Bony landmarks used	Position	Results
(Mino, et al., 1983)	To evaluate the relative value of routine radiography and CT in the diagnosis of DRUJ subluxation and dislocation	3 Cadaver extremities	CT and X-ray images were obtained from intact cadaver specimens. A review of these images was conducted after sectioning of soft tissue supporting structures. Each specimen was placed in 50% palmar subluxation/dislocation and 50% dorsal subluxation/dislocation.	<u>X-rays:</u> Radial carpal alignment was assessed relative to distal radius and ulna. <u>CT scan:</u> Radial ulna line method: sigmoid notch dorsal and volarly and ulna head.	Neutral, 45° supination, full supination, 45° pronation and full pronation. A fourth cadaver was positioned in 10° supination and 10° pronation for comparison	<u>X-ray</u> Neutral – views of palmar dorsal subluxation and dislocation could be determined whereas 10° pronation or supination altered ability to determine subluxation/dislocation. Full supination/pronation lateral views also altered the ability to interpret subluxation/dislocation with numerous false positives. <u>CT scan:</u> In all positions of rotation, a reduced DRUJ was able to be interpreted as was progressive palmar or dorsal dislocation.
(Pirela-Cruz, et al., 1991)	To determine the amount of translational motion taking place at the DRUJ using axial CT analysis	8 volunteers (16 DRUJ's) with no clinical evidence of instability	Participants placed in custom built radiolucent platform controlling position and stress. CT scans (5mm thick, 3mm spacing) of 3 stress positions; no stress, maximal ulna palmar stress and maximal ulna dorsal stress. Stress carried out by stabilising the radius with posts, an ulna post located over the ulna head was manually applied with constant force 20.3N palmar stress and 42.5N dorsal stress.	Lister's tubercle, dorsal ulna corner of radius, palmar border of ulna head	Prone and neutral forearm rotation	<u>Palmar stress</u> Normal translational motion 2.1mm (+/- 1.6mm) <u>Dorsal stress</u> Normal translation motion 1mm (+/- 0.9mm) No statistical significance for male vs. female, hand dominance or contralateral sides.

Study	Purpose	Participants	Method	Measurement & DRUJ Bony landmarks used	Position	Results
(Park & Kim, 2008)	To evaluate the repeatability of current CT methods for quantifying translation of the DRUJ and to determine normal population values.	45 participants with 45 asymptomatic wrists included in study	CT scans 3mm thickness of axial sections of the DRUJ. Forearm was placed in a custom designed positioning device including a handgrip bar to rotate the hand into positions of testing. Participant asked to hold handgrip firmly to avoid passive radiocarpal motion. Four methods were used to evaluate the images; RUL, Subluxation ratio, epicentre and RUR methods. Evaluated 3 months later also.	Scans with the largest areas of the sigmoid notch, ulna head (including ulna styloid) and Lister's tubercle were selected for analysis. Bony landmarks/method of each analysis as described above for all four methods.	Standing with lumbar spine bent laterally, elbow 90, and forearm in neutral, 70 pronation and 70 supination	<u>Dorsal translation (-ve value indicates volar translation)</u> <u>RUL</u> Pronation 0.16 Neutral 0.02 Supination -0.11 <u>Subluxation ratio</u> Pronation 0.20 Neutral 0.01 Supination -0.13 <u>Epicentre</u> Pronation -0.01 Neutral 0.09 Supination 0.11 <u>RUR</u> Pronation 0.66 Neutral 0.51 Supination 0.42 Overall subluxation ratio had greater inter and intra-observer repeatability
(Chiang, et al., 1998)	To investigate the clinical application and accuracy of three CT methods for diagnosis of DRUJ subluxation	40 patients with 17 symptomatic DRUJ's and 37 asymptomatic wrist (54 wrists)	Neutral posteroanterior and lateral x-rays and bilateral (asymptomatic and symptomatic sides) CT scans taken and assessed using each criteria including the RUL, Epicentre and congruity method. Sensitivity, specificity, positive predictive value (PPV) and negative predictive value (NPV) were calculated based on statistical methods	As described previously for each of the 3 methods of analysis	Neutral, full supination and full pronation	<u>RUL method</u> High sensitivity (100%) and NPV (100%) but average specificity (43.2%) and PPV(44.7%) <u>Epicentre method</u> Overall high sensitivity (82.4%) and specificity (94.6%) as well as high PPV (87.5%) and NPV (92.1%). <u>Congruity method</u> Medium to high sensitivity (76.4%) and high NPV (84.6%), although only medium specificity (59.5%) and low PPV (46.4%). Overall the epicentre method was superior particularly in specificity