

Gout on CT: a symmetric arthropathy.

Anthony J Doyle (corresponding author)

Objectives: To assess the distribution of bone erosions in the feet of patients with gout using computed tomography (CT) and thereby to test the hypothesis that gout is an asymmetric arthropathy.

Methods: CT scans of both feet were obtained from 25 patients with chronic gout. CT scans were scored for bone erosion using a semi-quantitative method based on the rheumatoid arthritis MRI scoring system (RAMRIS). CT bone erosion was assessed at 22 bones in each foot (total 1,100 bones) by two independent radiologists. Symmetry was assessed by two methods: a) comparing right and left foot scores for each patient; b) calculating the proportion of paired joints with or without erosions.

Results: Observer agreement was excellent (intra-class correlation coefficient 0.92). In the group overall, the difference in scores between the feet was not significant (Student T test $p=0.8$). In 17 of 25 patients, the difference in erosion scores between the two feet was less than the inter-observer difference. In 24 of 25 patients, the proportion of paired joints was greater than 0.5, indicating symmetric disease.

Conclusions: Erosive disease from gout is, in fact, a symmetric process in our patient group. This finding is contrary to the established view of gout as an asymmetric arthritis and lends new insight into the behaviour of this common disease.

Introduction

Gout is a common arthropathy worldwide and is often described in medical textbooks and review articles as being asymmetric [1-6]. However, there has been little formal research into the distribution of gouty lesions seen on imaging, particularly when using quantitative scoring systems. We used a set of high-resolution CT scans obtained from patients with gout and scored by two independent observers to analyse the distribution of erosive bone disease in the group, especially with regard to right/left symmetry.

Patients and Methods

Patients

Twenty-five adult patients with gout were recruited from rheumatology outpatient clinics in Auckland, New Zealand. The Northern Y Regional ethics committee approved the study and patients provided written informed consent according to the Declaration of Helsinki. As previously described [7], all patients had a history of acute gout according to ACR diagnostic criteria [8], and were excluded if they were experiencing an acute gout flare at the time of assessment, had lower limb amputation or diabetes mellitus. Information regarding age, gender, ethnicity, disease duration, presence of subcutaneous tophi, and other clinical characteristics of gout was recorded. Plain radiographs of the feet and blood for serum urate testing were also obtained on the day of assessment.

CT scans

The CT scans of the feet and ankles were performed on a Philips Brilliance 16-slice scanner (Philips Medical Systems, Best, The Netherlands). The patients were positioned supine with the knees bent to 90 degrees and the

feet dorsiflexed 45 degrees. Both feet were scanned together with the CT gantry vertical. The range covered was from 5cm above the ankle joint to the ends of the toes. All scans were performed with the same image protocol; acquisition at 16 x 0.75mm, reconstructed on a bone algorithm, 768 matrix, to 0.8mm slices with a 0.4mm increment. (kVp 140, 120 mAs/ slice). Additional reconstructions were done on a soft tissue algorithm, 512 matrix, also to a 0.8mm slice with a 0.4mm increment. The images were viewed as 0.8mm slices on a Philips CT workstation and reconstructed to 3mm slices for viewing on Picture Archiving Communication System (PACS).

CT scans were analyzed for bone erosion by two independent musculoskeletal radiologists (AD and LB) who were blinded to the clinical details, plain radiographic damage scores and each other's CT erosion scores. The radiologists used the overlapping thin slices to interactively generate multiplanar reformations on standard PACS workstations (Impax version 4, Agfa-Gevaert, Belgium; Osirix version 3.6, Osirix Foundation, Geneva, Switzerland). Bone erosion was assessed using reformatted images in the anatomic axial, sagittal and coronal planes. Erosions on CT were defined as focal areas of loss of cortex with sharply defined margins, seen in two planes, with cortical break seen in at least one plane. Bone erosion was scored using a semi-quantitative method based on the rheumatoid arthritis MRI scoring system (RAMRIS) [7]; each bone was scored separately on a scale from 0-10, based on the proportion of eroded bone compared to the "assessed bone volume", judged on all available images-0: no erosion; 1: 1-10% of bone eroded; 2: 11-20%, etc. For long bones and large tarsal bones, the "assessed bone volume" was from the articular surface (or its best

estimated position if absent) to a depth of 1 cm. Bone erosion was assessed at 22 bones in each foot (44 bones/patient) and in a total of 1,100 bones.

These sites were selected to include all bones in the foot and ankle except for the great toe distal phalanx and the lesser toe phalanges. The following bones were scored; distal and proximal portions of the 1st proximal phalanx, 1st-5th metatarsal (MT) heads, 1st-5th MT bases, lateral, middle and medial cuneiforms, navicular, cuboid, anterior process of calcaneus, proximal calcaneus, distal talus, proximal talus and distal tibia.

The erosion scores for right and left feet in each patient and in the group as a whole were compared for each observer and for the averaged scores of both observers using the Student T test. For the paired joint analysis, each joint was recorded as normal if the erosion score was zero and as diseased if the score was not zero. The number of matching pairs was then divided by the total number of joints counted; symmetry is equivalent to this ratio being 0.5 or greater.

Results

The clinical characteristics of the patients have been reported in detail previously [9]. In brief, 19 (75%) were male, 17 (68%) were non-Polynesian and 8 (32%) were of Maori or Pacific ancestry. The median (range) age was 60 (37–83) years and disease duration was 21 (1–50) years. Thirteen (52%) patients had clinical evidence of tophaceous disease, 11 (44%) had microscopically proven disease and 22 (88%) were on regular urate-lowering therapy (21 on allopurinol, 1 on probenecid). The median (range) serum urate was 0.35 (0.14–0.61) mmol/l. The median (range) gout radiographic damage score for the feet was 17 (0–70).

The overall erosion scores for right and left feet were very similar for each observer (Table 1). The observer intra-class correlation coefficient was 0.92, indicating excellent agreement. The observer intra-class correlation coefficient (95% CI) for the overall erosion scores was 0.92 (0.82,0.96); for the right feet 0.91(0.83, 0.95) and for the left feet 0.92(0.84,0.96) indicating excellent observer agreement. No significant difference was seen between the scores for right and left feet by observer ($p=0.8$ observer 1 and 0.7 observer 2); neither was there any difference between the averaged observer scores for right and left feet ($p=0.7$). Sub analysis of the erosion scores for the fore foot, mid foot and hind foot showed no right/left difference in any of these areas. (Table 2). A typical example of a patient with moderately advanced symmetric gout is shown in Figure 1.

The median (range) total CT erosion score (22 sites/patient) was 29 (5-106.5). The average (SD) difference between observer 1 and observer 2 scores for each foot was 5.22 (4.4). We used this average observer difference as a threshold for a significant right/left difference between the two feet. The average (SD) right/left combined observer score difference was 5.4 (6.4). In eight of 25 patients (32%), the right/left difference was greater than 5.22 points and deemed 'asymmetric' (Table 3). In each of these, the observers scored the asymmetry in same direction. Four patients had higher scores on the right, and four on the left. In the remaining 17 (68%) patients, the difference score was 4 or less; in 12 (48%), it was 2.5 or less.

Even in the patient with the highest degree of asymmetry, erosions were visible in similar sites on each foot (Figure 2).

The clinical features of the 'asymmetric' and 'symmetric' groups are given in Table 4. Patients in the asymmetric group were younger, but there was no significant difference in gender, disease duration, presence of tophi on physical examination or serum urate level. There was no difference in the mean total CT erosion score in the asymmetric group compared with the symmetric group (47.3(32.8) vs. 36.4(30.0), $p=0.44$).

Another mathematically based but less strict definition of symmetry was described by Helliwell in 2000 [10]. In this definition, a pair of joints is counted as symmetric if arthritis is recorded as being either present or absent bilaterally. Overall symmetry is defined as being present when the ratio of symmetric pairs of joints to the total number of pairs of joints observed is equal to or greater than 0.5. Using this definition, 24 of our 25 patients had symmetric disease. The only patient with asymmetric disease had a right/left score difference of 16.

Discussion

The traditional teaching in imaging of gout is that it is an asymmetrical arthritis, affecting one side of the body more than the other. Our results indicate that, at least in this patient group, the distribution of gouty erosions in the feet on CT was, in fact, quite symmetric in the vast majority of cases. This was regardless of gender, duration of disease, serum urate and total erosion score. The group with asymmetric disease was a little over ten years younger on average, a result whose significance is uncertain.

Previous studies have shown that CT and MRI are more reliable than radiographs for demonstrating erosions in both rheumatoid arthritis and gout, [11-13]. More recently, our group has validated a CT scoring method for gout [7] in which it was discovered that around 65% of the erosion score could be attributed to proximal joints not well seen on radiographs. It is probably reasonable to assume that the CT findings here can be taken as a reasonably true depiction of the actual erosive disease distribution.

Other work shows that erosive disease shown on imaging does correlate with clinical features of gout including tophus burden and functional indices such as grip strength [9,12]. It is likely that the bilaterally symmetric nature of the disease shown here will eventually be reflected clinically.

Several different explanations may account for the variance between our findings and the traditional view of gout as an asymmetric arthritis in imaging terms. One is that the degree of symmetry simply has not been formally investigated previously; there is very little quantitative data in the literature regarding radiographic findings in gout. Previous authors may have been

relying on the usual initial clinical presentation of gout as a monoarthritis being a feature that must inevitably be reflected radiographically.

Another possible explanation is that the disease begins in an asymmetric fashion and progresses toward symmetry with time. The radiographic signs of gout are said to emerge after 5-10 years' disease duration [14] and our patients had an average disease duration of about 20 years. However, disease duration was the same for the symmetric and asymmetric groups, a feature that does not favour duration alone as the determinant of symmetry. The most likely explanation, based on this and our group's previous work showing a high prevalence of mid and hind-foot disease [7], is that most patients with gout do have involved joints that are asymptomatic and that simply have not been detected with older imaging techniques, in particular plain radiographs.

As more research is performed into the features of gout on modalities such as CT, MRI and ultrasound where sensitivity is higher than that of radiographs, it may become clearer as to whether most gouty arthritis begins as a symmetric process or evolves into one. The current study, however, strongly suggests that the majority of patients with established gout do in fact have bilaterally symmetric disease.

Table 1. Erosion scores by foot and observer. Data are presented as mean (SD).

	Right foot	Left foot	p
Observer 1	20.0 (16.1)	20.5 (16.3)	0.8
Observer 2	19.3 (15.1)	20.0 (17.5)	0.7

Table 2. Fore, mid and hind foot scores. Data are pooled from both readers and presented as mean (SD).

	Right foot	Left foot	p
Fore foot	6.4(6.0)	6.7(6.5)	0.9
Mid foot	10.1(7.7)	10.8(10.1)	0.8
Hind foot	3.2(3.7)	2.8(2.9)	0.6

Table 3. Difference in erosion scores in asymmetric cases

Case	1	2	3	4	5	6	7	8
Mean	27	16.0	16.0	13.0	8.5	7.0	7.0	5.5
Observer 1	25	18	20	12	11	9	5	8
Observer 2	29	14	12	14	6	5	9	3
Side greater	left	right	right	left	left	right	left	right

Table 4. Clinical features of symmetric and asymmetric groups.

	Symmetric	Asymmetric	p
Age, years, mean (SD)	64(10.3)	53(11.0)	0.02
Male sex, n (%)	13 (76%)	6 (75%)	1.0
Disease duration, years, mean (SD)	22(15.2)	21(10.0)	0.8
Tophi on physical examination, n (%)	8(47)	5(63)	0.7
Serum urate, mmol/L, mean (SD)	0.36(0.1)	0.36(0.2)	0.9
CT erosion score, mean (SD)	36.4(30.0)	47.3(32.8)	0.44

References

1. Watt I, Middlemiss H. The radiology of gout. *Clin Radiol* 1975; 26: 27-36
2. Gentili A. Advanced Imaging of Gout. *Seminars in Musculoskeletal Radiology* 2003; 7: 165-174
3. Monu JUV, Pope TL. Gout: a clinical and radiologic review. *Radiol Clin N Am* 2004; 42:169-184
4. Resnick D, Kransdorf MJ. Gouty Arthritis. In: *Bone and Joint Imaging*. Philadelphia: Elsevier Saunders; 2005: 445-458.
5. Dhanda S, Jagmohan P, Tian QS. A re-look at an old disease: A multimodality review on gout. *Clin Radiol* 2011; 66: 984-992
6. Schumacher HR, Chen LX. Gout and other Crystal-associated Arthropathies. In: *Harrison's Principles of Internal Medicine*, 18th edition. Access Medicine, McGraw-Hill; 2012
7. Dalbeth N, Doyle A, Boyer L, et al. Development of a computed tomography method of scoring bone erosion in patients with gout: validation and clinical implications. *Rheumatology* 2011;50:410–416
8. Wallace SL, Robinson H, Masi AT, Decker JL, McCarty DJ, Yu TF. Preliminary criteria for the classification of the acute arthritis of primary gout. *Arthritis Rheum* 1977;20: 895–900.
9. Dalbeth N, Clark B, McQueen F, Doyle A, Taylor W. Validation of a radiographic damage index in chronic gout. *Arthritis Rheum* 2007;57:1067–73
10. Helliwell PS, Hetthen J, Sokoll K, Green M, Archeson A, Lubrano E, Veale D, Emery P. Joint symmetry in early and late rheumatoid and

psoriatic arthritis: Comparison with a Mathematical Model. *Arthritis Rheum* 2000; 43: 865-871

11. Perry D, Stewart N, Benton N et al. Detection of erosions in the rheumatoid hand; a comparative study of multidetector computerized tomography versus magnetic resonance scanning. *J Rheumatol* 2005;32:256–67.
12. Dalbeth N, Clark B, Gregory K et al. Mechanisms of bone erosion in gout: a quantitative analysis using plain radiography and computed tomography. *Ann Rheum Dis* 2009;68:1290–5
13. Carter JD, Kedar RP, Anderson S et al. An analysis of MRI and ultrasound imaging in patients with gout who have normal plain radiographs. *Rheumatology* 2009;48:1442–6.
14. Bloch C, Hermann G, Yu TF. A radiologic reevaluation of gout: a study of 2000 patients. *Am J Roentgenol* 1980, 134; 781-787

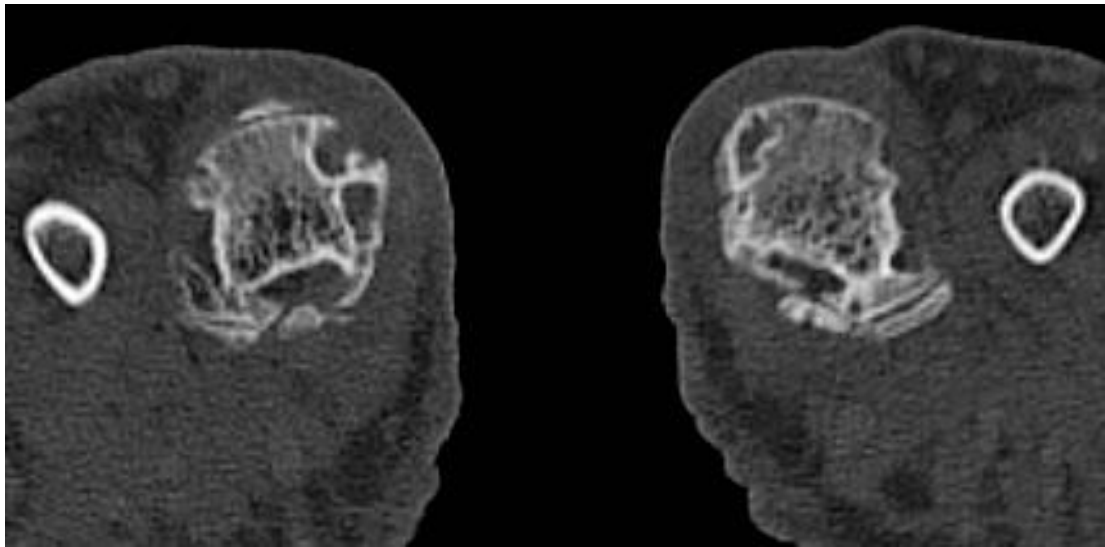


Figure 1A Fore foot erosions in patient with symmetric gout (score right=40, left=41)

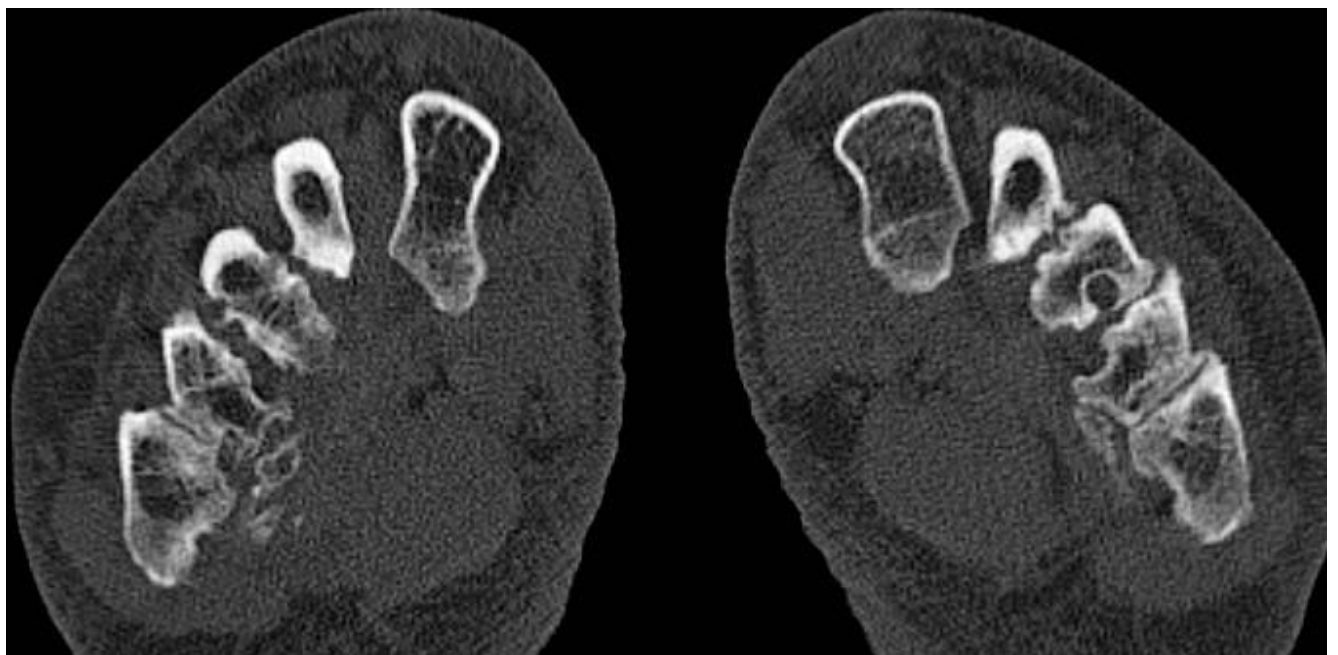

Figure 1B Mid foot erosions in patient with symmetric gout (score right=40, left=41)

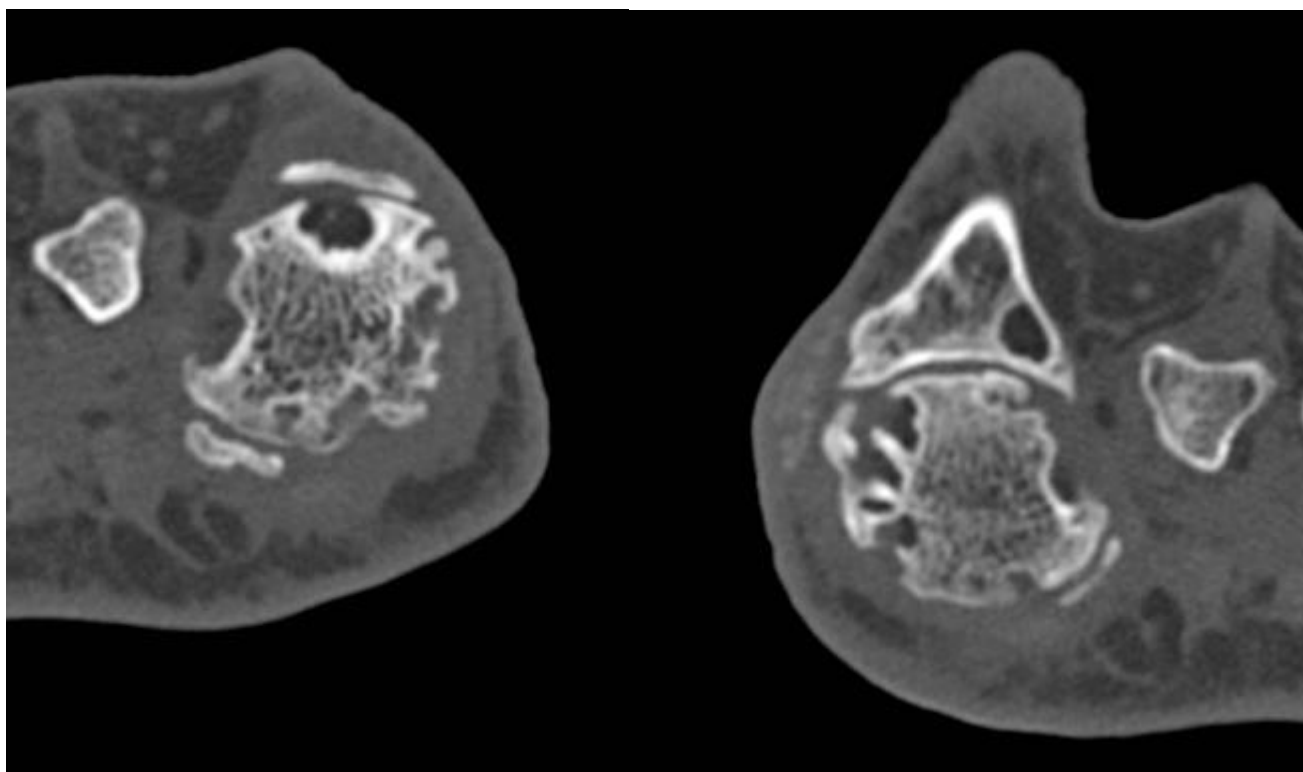


Figure 2A: Fore foot erosions in patient with asymmetric gout (score right=30, left=57) are slightly larger on left

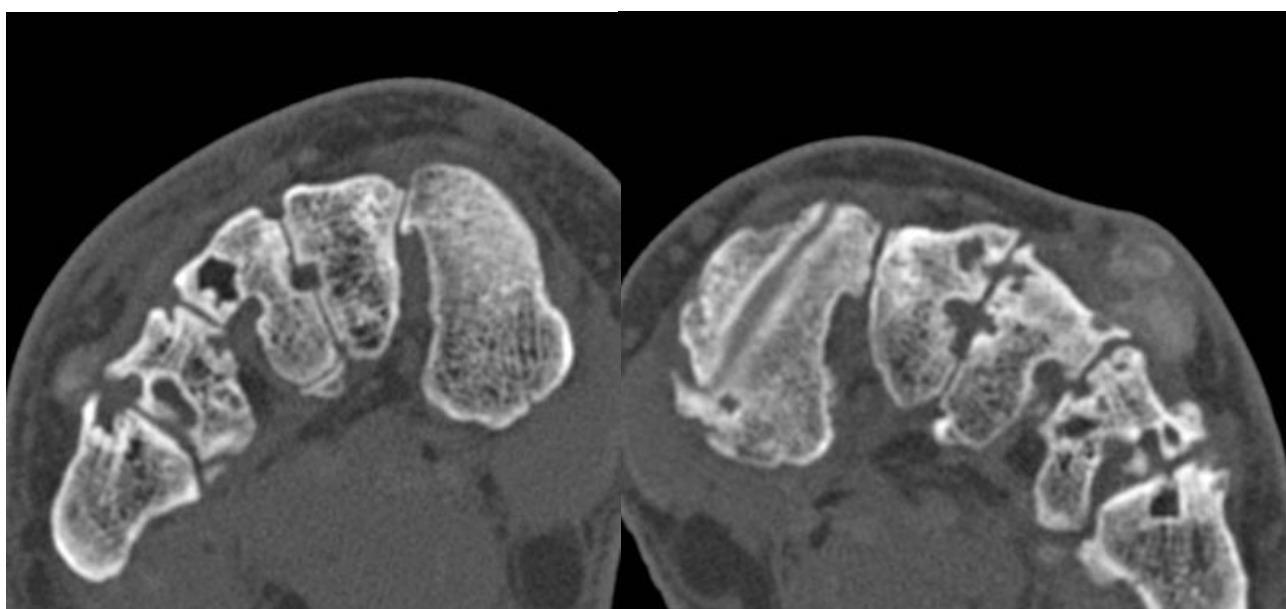


Figure 2B: Mid foot erosions in patient with asymmetric gout (score right=30, left=57) are slightly larger on left

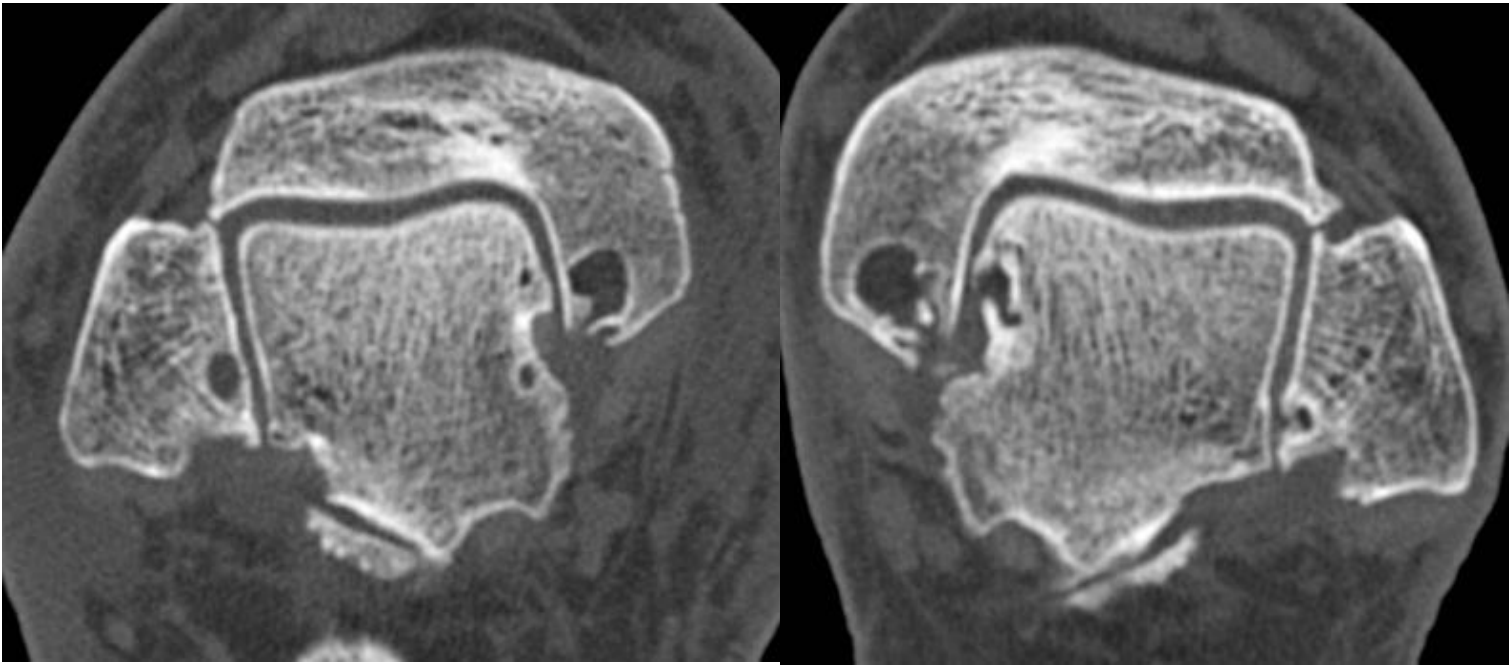


Figure 2B: Hind foot erosions in patient with asymmetric gout (score right=30, left=57) are slightly larger on left